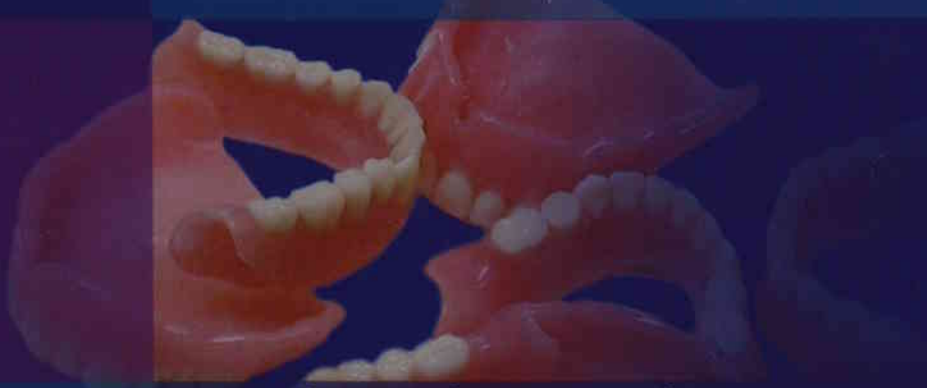

Hugh Devlin

# Complete Dentures



A Clinical Manual  
for the  
General Dental  
Practitioner



Springer

Devlin ■ **Complete Dentures**

This is a user-friendly guide to the principles of complete denture construction. It is a practical, extensively illustrated book for the general dental practitioner, starting with the examination of the edentulous patient and progressing through the different treatments in a logical way. A range of procedures has been described in sufficient detail so that the dentist can apply the best treatment measure to the specific clinical problem. A final chapter on domiciliary treatment has been included because elderly, house-bound patients often present problems such as denture retention (because of the patients' residual ridge atrophy or insufficient muscular control). Reference to original research work has been included so that the reader can explore the research evidence for himself.

ISBN 3-540-42183-1



<http://www.springer.de>

50.1 DEV

Hugh Devlin PPN 059731850

# Complete Dentures

A Clinical Manual  
for the General Dental Practitioner

PPN 059731885

With 72 Figures in Color

Imo 9626



Springer



074 008027 9

---

Dr. Hugh Devlin, B.D.S., B.Sc., M.Sc., Ph.D.  
Senior Lecturer in Restorative Dentistry  
University Dental Hospital of Manchester  
Higher Cambridge Street  
Manchester M15 6FH, United Kingdom  
(e-mail: Hugh.Devlin@man.ac.uk)

ISBN 3-540-42183-1  
Springer-Verlag Berlin Heidelberg New York

CIP Data applied for.

Die Deutsche Bibliothek - CIP-Einheitsaufnahme  
Devlin, Hugh: Complete dentures : a clinical manual for the general dental practitioner / Hugh Devlin. - Berlin; Heidelberg; New York; Barcelona; Hong Kong; London; Milan; Paris; Tokyo: Springer, 2002  
ISBN 3-540-42183-1

This work is subject to copyright. All rights are reserved, whether the whole or part of the material is concerned, specifically the rights of translation, reprinting, reuse of illustrations, recitation, broadcasting, reproduction on microfilm or in any other ways, and storage in data banks. Duplication of this publication or parts thereof is permitted only under the provision of the German Copyright Law of September 9, 1965, in its current version, and permission for use must always be obtained from Springer-Verlag. Violations are liable for prosecution under the German Copyright Law.

Springer-Verlag Berlin Heidelberg New York  
a member of BertelsmannSpringer  
Science+Business Media GmbH

<http://www.springer.de>

© Springer-Verlag Berlin Heidelberg 2002  
Printed in Germany

The use of general descriptive names, registered names, trademarks, etc. in this publication does not imply, even in the absence of a specific statement, that such names are exempt from the relevant protective laws and regulations and therefore free for general use.

Product liability: The publisher cannot guarantee the accuracy of any information about the application of operative techniques and medications contained in this book. In every individual case the user must check such information by consulting the relevant literature.

Cover-Design: Erich Kirchner, Springer-Verlag Heidelberg  
Typesetting: Data conversion by Springer-Verlag Heidelberg  
Printing and bookbinding: H. Stürtz AG, Würzburg

Printed on acid-free paper.  
SPIN 1073 0102 24/3130 ih - 5 4 3 2 1 0



---

## Preface

Unfortunately, many general dental practitioners say they do not enjoy constructing complete dentures, describing it as something akin to a black-art. In this book, I wanted to describe the practical procedures and the science behind many of our actions in the clinic so that successful treatment can be applied to patients. So, surprisingly for a manual, the text is analytical, with a critical discussion of pertinent references to published research. I have sought a balanced approach throughout, avoiding controversy for its own sake. The written text has been reduced to the minimum required to explain the principles and techniques of denture construction. Although this book has been written primarily for general dental practitioners, it is hoped that it may also be useful for undergraduate and postgraduate students.

Providing satisfactory complete dentures for patients is demanding work, requiring excellent technical, diagnostic and communication skills. If the current epidemiological trends continue, fewer people in the developed world will require complete dentures, but the complexity of treatment is likely to increase as patients' expectations rise. Unfortunately, significant numbers of elderly patients continue to be rendered edentulous late in life when their powers of adaptation to new dentures are much reduced.

This manual is the result of discussions with many past and present members of the University Dental Hospital of Manchester. I would like to express my sincere appreciation to my friends Drs. John Heath and Gillian Hoad-Reddick for their guidance and help over the years.

It is also a pleasure to thank the editorial and technical staff of the medical publishers Springer-Verlag for their advice during preparation of the text and their skill in printing and reproduction.

Summer 2001

Hugh Devlin

---

# Contents

|                                                                      |    |
|----------------------------------------------------------------------|----|
| <b>1 Treatment Planning:</b>                                         |    |
| <b>Assessing the Task Ahead</b> .....                                | 1  |
| The Examination of the Patient .....                                 | 2  |
| History of the Patient's Complaint .....                             | 2  |
| The Gagging Patient .....                                            | 3  |
| Medical History .....                                                | 3  |
| Examination of the Extraoral Tissues .....                           | 4  |
| Examination of the Oral Tissues .....                                | 5  |
| Examination of the Dentures .....                                    | 6  |
| Denture Retention .....                                              | 6  |
| Denture Stability .....                                              | 6  |
| Denture Occlusion .....                                              | 6  |
| Examination of the Hard Tissues .....                                | 7  |
| Examination of the Soft Tissues:                                     |    |
| Denture Stomatitis .....                                             | 8  |
| Treatment of Denture Stomatitis .....                                | 10 |
| Adjusting the Occlusion in Patients<br>with Denture Stomatitis ..... | 10 |
| Cleaning the Dentures in Patients<br>with Denture Stomatitis .....   | 12 |
| Improving Tissue Adaptation in Patients<br>with Denture Stomatitis:  |    |
| Technique for Chairside Reline .....                                 | 12 |
| Resilient Lining Materials .....                                     | 13 |
| Other Soft Tissue Abnormalities .....                                | 13 |
| Prognosis of Treatment .....                                         | 14 |
| References .....                                                     | 14 |

|                                                                                       |           |
|---------------------------------------------------------------------------------------|-----------|
| <b>2 Impression Taking and Mucosal Loading .</b>                                      | <b>17</b> |
| Anatomy of Mucosal Tissues .....                                                      | 18        |
| How Does Oral Mucosa Behave in Function? ...                                          | 18        |
| The Principles of Impression Procedures .....                                         | 19        |
| Impression Taking Procedures .....                                                    | 20        |
| The Mucostatic Impression Technique ...                                               | 20        |
| The Mucocompressive<br>Impression Technique .....                                     | 20        |
| The Selective Mucocompressive<br>Impression Technique .....                           | 21        |
| Disinfection Procedures .....                                                         | 21        |
| The Impression in the Maxillary Region .....                                          | 21        |
| The Primary Compound Impression .....                                                 | 21        |
| The Secondary Alginate<br>Maxillary Impression .....                                  | 22        |
| The Mandibular Impression .....                                                       | 25        |
| The Lower Compound<br>Primary Impression .....                                        | 25        |
| The Lower Special Tray Impression<br>Using Zinc Oxide/Eugenol Paste .....             | 26        |
| Selective-pressure Impression<br>for the Lower Ridge .....                            | 28        |
| The Upper Selective-pressure<br>Impression Technique .....                            | 28        |
| Occlusal Considerations with a Fibrous Ridge ..                                       | 30        |
| Should Load Be Deliberately Applied<br>to the Tissues During Impression Procedures? . | 31        |
| The Gagging Patient:<br>Are Impression Procedures Possible? .....                     | 31        |
| References .....                                                                      | 32        |
| <br>                                                                                  |           |
| <b>3 Determining the Jaw Relationship .....</b>                                       | <b>33</b> |
| How Does the Temporomandibular Joint Move<br>During Function? .....                   | 35        |
| Clinical Determination of the Jaw Relationship .                                      | 37        |
| Laboratory Construction of Occlusal Rims ....                                         | 37        |

|                                                                     |    |
|---------------------------------------------------------------------|----|
| Adjusting the Upper Occlusal Rim in the Clinic                      | 37 |
| Determining the Angulation<br>of the Occlusal Plane                 | 38 |
| The Residual Ridge                                                  | 38 |
| Alar-Tragal Plane (or Camper's plane)                               | 39 |
| The Parotid Papilla                                                 | 39 |
| Other Methods Available<br>to Obtain the Occlusal Plane Orientation | 39 |
| High Lip Line, Canine Lines,<br>and Centre Lines                    | 39 |
| Recording the Mandibular Rest Position                              | 40 |
| Alternative Techniques that Use<br>the Swallowing Reflex            | 40 |
| Recording the Horizontal Jaw Relationship                           | 41 |
| Alternative Techniques that Use<br>Graphical Methods                | 42 |
| Methods of Selecting the Anterior Teeth                             | 42 |
| Positioning the Anterior Teeth Correctly                            | 43 |
| The Upper Central Incisor Teeth                                     | 43 |
| The Maxillary Lateral Incisor                                       | 43 |
| The Maxillary Canines                                               | 45 |
| Arranging the Mandibular Anterior Teeth                             | 45 |
| Positioning the Posterior Teeth                                     | 46 |
| The Maxillary Premolar Teeth                                        | 47 |
| The Maxillary Molar Teeth                                           | 47 |
| The Mandibular Posterior Teeth                                      | 47 |
| Anatomical Guides to Positioning<br>the Posterior Teeth             | 48 |
| Biometric Guidelines                                                | 48 |
| Width of the Maxillary Arch                                         | 48 |
| The Inter-Ridge Space                                               | 49 |
| Alternative Occlusal Arrangements<br>of Posterior Tooth             | 50 |
| Occlusal Pivot Appliances                                           | 50 |
| Nonanatomical Teeth Set<br>on a Flat Occlusal Plane                 | 51 |
| Plaster-Pumice Occlusal Rims                                        | 51 |
| Metal Template Guides                                               | 52 |
| Lingualized Occlusion                                               | 52 |
| The Morphology of the Denture Space                                 | 55 |

|                                                                   |           |
|-------------------------------------------------------------------|-----------|
| Clinical Physiology Studies .....                                 | 56        |
| Impression Techniques to Record<br>the Muscular Environment ..... | 56        |
| Clinical Methodology for Recording<br>the Denture Space .....     | 57        |
| Research Studies .....                                            | 58        |
| Modifying the Buccal Surface of the Denture                       | 58        |
| Other Muscle Activity in Denture Retention ...                    | 58        |
| References .....                                                  | 59        |
| <br>                                                              |           |
| <b>4 The Trial Denture .....</b>                                  | <b>63</b> |
| Retention and Stability in the Patient's Mouth ..                 | 63        |
| Anterior Tooth Position .....                                     | 65        |
| Horizontal and Vertical Jaw Relationship .....                    | 68        |
| Developing Balanced Articulation<br>with Anatomical Teeth .....   | 69        |
| Articulation with Cuspless Posterior Teeth ..                     | 70        |
| Articulation in Lingualized Occlusion .....                       | 70        |
| Simple Hinge Articulators .....                                   | 70        |
| Average Value Articulators .....                                  | 71        |
| The Facebow .....                                                 | 72        |
| Adjustable Articulators .....                                     | 72        |
| The Closest Speaking Distance .....                               | 72        |
| Colouring the Labial Flange .....                                 | 73        |
| Postdam .....                                                     | 73        |
| Undercuts .....                                                   | 74        |
| Providing Tin-Foil Relief .....                                   | 74        |
| Liaison with the Laboratory .....                                 | 74        |
| The Complete Upper Denture .....                                  | 75        |
| The Complete Lower Denture .....                                  | 76        |
| References .....                                                  | 77        |

|                                              |    |
|----------------------------------------------|----|
| <b>5 Fitting the Processed Denture</b> ..... | 79 |
| Remounting Procedures .....                  | 81 |
| Occlusal Adjustment                          |    |
| Using an Average Value Articulator .....     | 81 |
| Occlusal Adjustment Using a Facebow          |    |
| Registration and Articulator .....           | 81 |
| Denture Retention .....                      | 83 |
| Aesthetic Appearance .....                   | 83 |
| Patient's Instruction Leaflet .....          | 83 |
| Denture Fixative .....                       | 84 |
| References .....                             | 84 |
| <br>                                         |    |
| <b>6 The Review Appointment</b> .....        | 85 |
| History of the Complaint .....               | 86 |
| The Painful Denture .....                    | 86 |
| Persistent Pain .....                        | 89 |
| Occlusal Loading of the Oral Tissues         |    |
| and Resilient Lining Materials .....         | 90 |
| Properties of the Different Types            |    |
| of Resilient Lining Materials .....          | 91 |
| Other Causes of Persistent Pain .....        | 91 |
| Defective Speech .....                       | 91 |
| “Unable to Chew Food Properly” .....         | 92 |
| Vague Symptoms .....                         | 92 |
| Burning Mouth Syndrome .....                 | 93 |
| Summary .....                                | 93 |
| References .....                             | 94 |
| <br>                                         |    |
| <b>7 Domiciliary Treatment</b> .....         | 95 |
| Scope of Domiciliary Treatment .....         | 96 |
| Denture Cleaning .....                       | 96 |

---

|                                                          |            |
|----------------------------------------------------------|------------|
| Denture Marking .....                                    | 98         |
| Clinical Technique .....                                 | 98         |
| Domiciliary Prosthetic Treatment .....                   | 99         |
| Denture Looseness .....                                  | 99         |
| Technique for Relining Upper<br>and Lower Dentures ..... | 100        |
| Template Dentures .....                                  | 100        |
| Repair of Dentures .....                                 | 103        |
| Stages Involved in Denture Repair .....                  | 103        |
| Other Causes of Fractured Dentures .....                 | 103        |
| References .....                                         | 105        |
| <br>                                                     |            |
| <b>Subject Index .....</b>                               | <b>107</b> |



---

# 1 Treatment Planning: Assessing the Task Ahead

|                                                                      |    |
|----------------------------------------------------------------------|----|
| The Examination of the Patient .....                                 | 2  |
| History of the Patient's Complaint .....                             | 2  |
| The Gagging Patient .....                                            | 3  |
| Medical History .....                                                | 3  |
| Examination of the Extraoral Tissues .....                           | 4  |
| Examination of the Oral Tissues .....                                | 5  |
| Examination of the Dentures .....                                    | 6  |
| Denture Retention .....                                              | 6  |
| Denture Stability .....                                              | 6  |
| Denture Occlusion .....                                              | 6  |
| Examination of the Hard Tissues .....                                | 7  |
| Examination of the Soft Tissues:                                     |    |
| Denture Stomatitis .....                                             | 8  |
| Treatment of Denture Stomatitis .....                                | 10 |
| Adjusting the Occlusion in Patients<br>with Denture Stomatitis ..... | 10 |
| Cleaning the Dentures in Patients<br>with Denture Stomatitis .....   | 12 |
| Improving Tissue Adaptation in Patients<br>with Denture Stomatitis:  |    |
| Technique for Chairside Reline .....                                 | 12 |
| Resilient Lining Materials .....                                     | 13 |
| Other Soft Tissue Abnormalities .....                                | 13 |
| Prognosis of Treatment .....                                         | 14 |
| References .....                                                     | 14 |

It is often stated that the need for complete denture treatment will decline as the elderly retain more of their teeth for longer. Surveys over the last 30 years have shown a steady improvement in dental health in the industrialized communities of Europe and the United States. While the dental health of the majority in these countries is improving, those in the lower socioeconomic groups, such as the elderly, have the worst dental health and the highest rates of edentulousness. Looking to the future, people are living longer with the number of centenarians due to increase dramatically (Velkoff 2000), so it should be many years before a dramatic reduction in edentulousness is observed in this segment of the population.

## The Examination of the Patient

When a patient requests complete dentures, it can be the end-result of a lifetime of varied denture-wearing experiences. They may have totally satisfactory complete dentures or extensive partial denture experience but their remaining natural teeth are very mobile and painful. Alternatively, they may have little denture wearing experience or only unpleasant memories of past unsuccessful dentures. Elderly patients can find adapting to new dentures an unpleasant experience and conditions such as xerostomia and radiotherapy, combined with a sugar-rich diet, can cause rampant caries and necessitate removal of the patient's teeth late in life. The treatment may present different levels of difficulty and require a range of approaches.

To be able to arrive at a diagnostic prescription for the design of the new complete denture, there must first be an extensive fact-gathering exercise. If the patient already has dentures, the patient's complaint must be noted and an attempt made to diagnose the cause of the complaint. The treatment plan will then address whether or how the complaint can be rectified.

## History of the Patient's Complaint

Many patients simply request replacement dentures as their present dentures have become ill-fitting and uncomfortable. Relining or rebasing their existing dentures may be successful and straightforward. However, in those situations where it has been unsuccessful for some reason, the patient will no longer be able to wear the denture. Relining existing dentures should not be embarked on lightly – it is not a panacea and will only correct a lack of retention. Even then, poor retention may be due to many other factors, e.g. overextension or adverse anatomical factors, which are not remedied by relining procedures.

Increasing numbers of individuals are reaching old age with their own natural teeth. It is important for those patients with missing natural teeth to have obtained some partial denture-wearing experience in middle age. Without this experience, newly provided dentures for the elderly individual have a much re-

duced prognosis. Debilitating medical and mental illness is more likely in the elderly, further limiting successful new denture wearing.

In recent years, the “shortened dental arch concept” has been introduced as a treatment strategy designed to prioritize treatment in those in whom a full arch occlusion cannot be provided. Patients can function adequately using natural anterior and premolar teeth (Witter et al. 1999). However, if further natural teeth are lost later in life, then it may be difficult to provide successful complete dentures. The tongue and cheeks may have spread to occupy the posterior edentulous spaces, and the oral musculature may be unable to adapt to the efforts required to control the new prosthesis.

Far more satisfactory may be the addition of teeth to the patient’s existing partial denture as the natural dentition is reduced following periodontal disease and/or caries. One disadvantage is that patients must be without their denture while the technician adds the artificial tooth to the denture. The laboratory technician is provided with an alginate impression of the denture in situ, together with an impression of the opposing arch and interocclusal wax record, if necessary. Denture-wearing experience obtained in youth or middle age provides valuable training in neuromuscular control of the dentures for the elderly patient to achieve an effortless transition to complete denture wearing.

Preserving even a few teeth or roots can often simplify treatment and has great psychological value for the patients (Fenton 1998). The roots preserve alveolar bone, and as overdentures are stable and retentive, function is often better than with conventional complete dentures.

### The Gagging Patient

Some patients express disquiet at the prospect of having examining mouth mirrors placed in their mouth because of the nausea and the gagging sensation that this induces. Their fear may result from having impressions taken previously. Strongly flavoured impression materials can stimulate salivary flow. Therefore, when taking the impressions the patient’s head must be held down and forward to prevent the sensation of choking that results from the accumulation of saliva at the back of the throat. The dental nurse places a bowl under the patient’s chin to collect the excess saliva.

If the patient is wearing a denture already, then the prognosis for successful treatment is better. Placing a reassuring hand on the patient’s shoulder or a few words of encouragement can often be enough to allay the patient’s fears.

### Medical History

Some common medical conditions may affect the success of prosthetic treatment. A denture requires saliva for adequate adhesion to the underlying mucosa.

In addition, an adequate amount and consistency of saliva is necessary for movement of the oral tissues over the polished surfaces of a denture. Often patients are taking drug therapy which may cause dryness of the mouth (xerostomia). Drugs with an anticholinergic effect, for example antihistamines and cyclic antidepressants, are particularly likely to cause this problem. In discussion with the patient's general medical practitioner, management may include substitution of a nonanticholinergic drug or provision of artificial saliva. Symptoms of dryness, burning mucosa and altered taste sensation may be due to diabetes mellitus; these patients should be medically investigated. Iron deficiency anaemia is a common problem in the elderly, because difficulties in mastication with ill-fitting dentures may restrict them to a poorly nutritious diet. The resultant hypochromic anaemia causes pallor of the mucosa, and may also be associated with recurrent oral ulceration, epithelial atrophy (especially of the tongue) and leucoplakia.

It is important to assess the degree of neuromuscular control of complete dentures, as it is vitally important in denture retention, by asking the patient to bite on the handle of a mirror, whereupon the dorsum of the tongue should be raised to support the back edge of the upper denture. Alternatively, watching the patient chew a biscuit can be informative. The complete denture wearer often lacks the precision of occlusal contact seen with dentate individuals, due to the lack of proprioception in the periodontal membrane. Even occlusal contact in lateral excursions is therefore necessary to allow the denture to be resealed during mastication.

## Examination of the Extraoral Tissues

The appearance of the face is examined, noting the muscle tone and colour and texture of the patient's skin. The skeletal relationship can be ascertained by examining the patient's profile, noting any abnormal size of the maxilla or mandible which may complicate denture provision. The skeletal classification may limit the position that the artificial incisor teeth can assume in the replacement dentures. For example, lower denture instability will result from a patient with a severe skeletal class II relationship wearing dentures with the lower incisor teeth set forward in an Angle's class I relationship. The lower lip will continually displace the lower denture backwards. The pre-extraction classification of the natural incisor teeth can be assessed from photographs, articulated models and immediate dentures.

The amount of interocclusal clearance (freeway space) should be noted. Old, worn dentures are often associated with an increased interocclusal clearance and angular cheilitis.

The symmetry of the face and lips at rest should be observed. The patient should be asked to open and close the mouth and any deviation of the mandible, clicking or crepitus at the temporomandibular joint noted. Any swelling of the face or lymph nodes is noted and investigated.

## Examination of the Oral Tissues

A visual, tactile and, if necessary, a radiographic examination should be performed. The dentist assesses the oral tissues for the presence of disease and for any features that will influence the provision of dentures. A detailed examination of the tissues is mandatory prior to commencing impression taking.

Extraorally, the skeletal classification of the jaw relationship, the facial symmetry, and facial tissues should be examined. Intraorally, the lips and cheeks, residual ridges, tongue and floor of the mouth should be inspected. The tongue tip can be grasped with a gauze napkin and raised to expose the floor of the mouth and retromolar areas.

Ideally, the residual ridges should be of moderate height with a rounded shape. On gentle palpation, the mucosa should be firm and not painful. The patient may present with a sharp bony residual ridge or mylohyoid ridge, which are painful when lightly pressed. If the residual ridge is uneven and irregular then movement of the lower denture during function can be painful. Incorporation of a resilient liner in the fitting surface of the new lower denture can do much to relieve these symptoms.

A prominent maxillary or mandibular torus can result in pain due to the thin overlying mucosa. If large, the denture base may cramp the tongue, especially if relief of the fitting surface of the denture is provided. If large and lobulated, surgical reduction may be necessary. The displaceability of the tissues in the area of the postdam will determine the adequacy of the posterior palatal seal. This is measured by gentle palpation of the palatal tissues. At the same time, the tolerance of the patient to nausea and the gagging reflex can be assessed in a gentle manner.

Denture granulomas result from longstanding irritation from an overextended flange and traumatic occlusion. They can be reduced in size by relieving the denture and adjusting the occlusion with self-curing acrylic resin. Preferably, though, the patient should discontinue wearing the denture. Some reduction in size of the denture granuloma can be expected, but the hyperplastic tissue often requires surgical removal. Removal of papillary hyperplasia may also be required using cautery. The patient's denture should be relined with a tissue-conditioning material, replacing it at intervals until healing has taken place. Only when the patient's mouth is in a healthy state should new denture treatment be commenced.

There is no place for the routine radiographic screening of patients for bone pathology in the absence of signs or symptoms of disease. The detection of asymptomatic roots has often been used as a justification for using screening panoramic radiography. Root fragments are commonly found in radiography surveys (Barclay and Donaldson 1970), but there is often no reason for their surgical removal. Indeed, the retention of noninfected roots has been shown to be an effective method of retaining the bone of the residual ridge. Even when radiographs are taken, incorrect positioning of edentulous patients for panoramic radiography is common (Glass et al. 1994), causing difficulties in interpretation. In-

traoral radiography is free from the artefacts that often affect the diagnostic accuracy of panoramic radiographs. Therefore, where symptoms from infected teeth or roots are present, an intraoral radiographic examination should be used in the first instance rather than panoramic radiography (Rushton and Horner 1996). This strategy would improve the diagnostic yield and reduce the cost to health service providers.

## Examination of the Dentures

### *Denture Retention*

The posterior edge of the upper denture, or postdam area, is of vital importance in denture retention, particularly during speech. The ingress of saliva and air under the upper denture is prevented by gently compressing the mucosal tissues in this area. Its correct positioning at the junction of the mobile and immobile areas of the palate can greatly aid denture retention.

Peripheral seal is the contact formed by the marginal surface of the denture with the oral mucosa. An adequate width of acrylic flange is necessary to contact the buccal mucosa at rest. If the denture is quickly pulled away from the tissues, the buccal mucosa is drawn in against the denture and resists further movement. The ability to provide an adequate peripheral seal in the lower denture is limited by the potential for air leakage lingually and at the retromolar pads. The lower denture should extend into the retromylohyoid space to avoid a displacing contact of the tongue with the distal edge of the lower lingual flange.

### *Denture Stability*

Denture stability is the resistance offered by the tissues to occlusally applied functional loads. Stability of the lower denture usually presents the most difficulty, but is aided by orientating the lower teeth over the residual ridge.

### *Denture Occlusion*

One of the commonest reasons for replacing dentures is the wear of the occlusal surface that occurs over time. When at rest, the space between the occlusal surfaces of the incisor teeth is normally about 2–4 mm, but as a result of bone resorption and tooth wear this distance may be increased. Patients with a large interocclusal space present in their dentures do not adapt to a large reduction with the new dentures. A conservative reduction of interocclusal space in these patients is better than immediate restoration of the standard 2–4 mm.

The occlusion of the dentures is examined. The lower denture must be stabilized by holding down the buccal flange with the forefingers. The patient is asked



to curl their tongue to touch the back edge of the upper denture and close together. The intercuspal position, i.e. the occlusion with maximum intercuspation of the teeth, should be coincident with the retruded contact position, i.e. the occlusal contact with the condyles in their most posterior position. The occlusal surfaces of the teeth during lateral and protrusive excursions of the mandible should lack any uneven or premature contacts. This can be difficult to detect visually and articulating paper may be required.

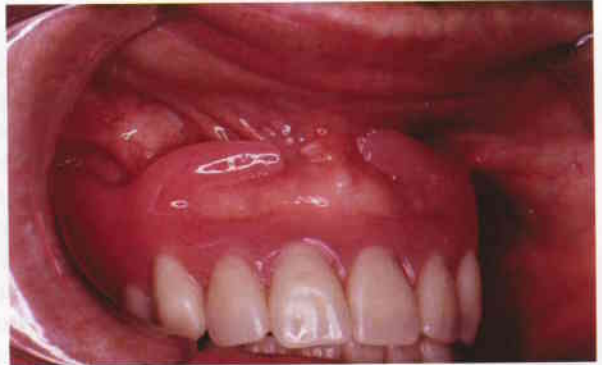If the last molar tooth is placed on the ridge as it slopes steeply up to the retromolar pad, pressure on that tooth with a finger will tilt the denture forwards.

## Examination of the Hard Tissues

The alveolar ridge following tooth extraction undergoes a progressive, irreversible resorption. The mandibular residual ridge is resorbed faster than the maxillary ridge, despite the greater bone density of the mandible. The denture-bearing area in the mandible is smaller than in the maxilla. The more severe mandibular resorption may be due to the small area available to support the mandibular denture, which is therefore subjected to a greater masticatory force per unit area. Others claim that systemic factors such as the menopause cause residual ridge resorption, but the evidence supports a multifactorial cause.

In a randomized cross-sectional study of 300 dried skulls, Cawood and Howell (1988) described the sequence of changes in shape of the residual ridges following tooth extraction. The ridge at first becomes knife-edged (becoming thinner in width but maintaining height) before becoming flat and finally totally resorbed. Resorption of basal bone and a negative ridge profile is possible. There are differences in the direction of bone resorption in different areas of the mouth. In the anterior part of the jaws, the direction of resorption is vertical and in a labiolingual direction. Posteriorly, the maxillary residual ridge undergoes vertical and buccopalatal resorption, while the mandibular ridge is resorbed in a mainly vertical direction.

**Fig. 1.1.** The prominent premaxilla prevented a conventional flange in this patient



In the anterior maxilla, the residual ridge may be prominent with the result that placement of a new denture with an anterior flange may cause an unnatural appearance of a swollen lip. This will necessitate extensive adjustment to allow denture insertion. Thus the width of the flange or its length may have to be reduced or alternatively a "winged" flange may be used with extensions above the premaxilla (Fig. 1.1, p. 7).

### Examination of the Soft Tissues: Denture Stomatitis

This is characterized by inflammation of the palate, with the erythema limited in outline by the fitting surface of the denture. The patient is often unaware of the condition because it is usually painless.

Denture stomatitis is classified into three types (Newton 1962):

Newton's type I: hyperaemia, which is associated with trauma (Fig. 1.2).

Newton's type II: generalized erythema.

Newton's type III: papillary hyperplasia, only resolved by surgery (Fig. 1.3).

The prevalence of denture stomatitis varies from 25% to 65%, depending on the population studied (Wilson 1998), but is an extremely common condition. In elderly patients, the increased incidence of disability following conditions such as stroke, may limit their ability to effectively clean their dentures. Poor denture hygiene, continuous denture wearing and drug therapy (especially antibiotics and steroid sprays) may lead to an increased frequency of yeast infection.

The aetiological factors in denture stomatitis are denture trauma and poor oral hygiene, with a superimposed fungal infection (usually *Candida albicans*). Denture stomatitis is more common in those patients who wear their dentures night and day. Denture stomatitis is therefore difficult to eliminate because patients do not change their denture-wearing habits easily. Patients may perceive that denture stomatitis is painless and a fairly trivial condition of little consequence. It is important for the dentist to diagnose and treat denture stomatitis because the inflammation of the tissues can compromise the retention of the newly constructed denture. To effect a practical change in denture cleansing behaviour, the dentist must reinforce the new behaviour on a regular basis. Effective mechanical cleaning of dentures with soap and a brush is unpopular with patients as advertising exerts a strong influence on patients' choice of denture cleanser (Burnett et al. 1993) and they often prefer commercial cleansers. Also, many patients with physical disabilities, such as arthritis, find denture scrubbing difficult.

The role of *C. albicans* in denture stomatitis is very controversial, as hyphal invasion of the epithelial surface is rarely seen. *Candida* species may be present as commensal organisms in the normal healthy human population. The effect of trauma in denture stomatitis may be to cause an inflammatory exudate which improves the adherence of *C. albicans* to the denture surface. Samaranyake et al.



Fig. 1.2. Newton's type I denture stomatitis with diffuse areas of palatal erythema that are usually caused by denture trauma

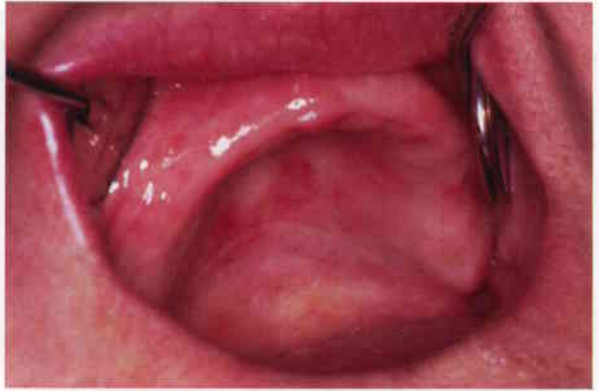
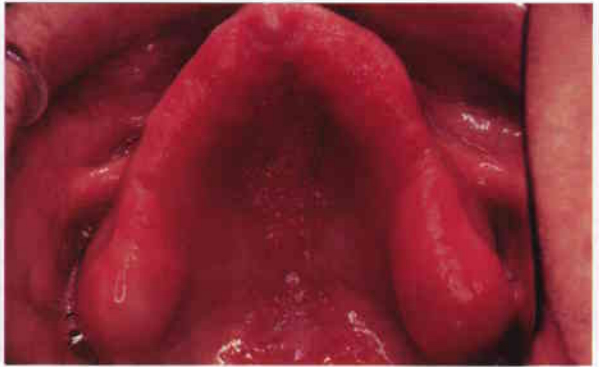
Fig. 1.3. Newton's type III denture stomatitis, with palatal hyperplasia (as well as generalized palatal erythema)



(1980) have shown that this organism attaches better to acrylic strips in vitro if the plastic is coated with serum.

Despite the difficulty of transporting the organism and its demanding growth requirements, *Candida* species can be isolated from up to 60% of healthy individuals (Wilson 1998). In patients with denture stomatitis, no *C. albicans* is seen to penetrate the denture acrylic, but is present in high concentration on the denture surface, especially in porous and undercut areas (Davenport 1972). There is a higher loading of *C. albicans* on the denture than on the oral mucosa.

Antifungal agents do not need to be prescribed routinely (Walker et al. 1981) and if used alone result in relapse and failure to resolve the condition. These drugs should be prescribed only where denture stomatitis fails to resolve and fungal involvement has been confirmed. Typical antifungal drug formulations are nystatin pastilles and amphotericin lozenges, which dissolve in the mouth and are used after the dentures have been removed. Miconazole gel can be used for short periods when applied to the fitting surface of the denture. However, miconazole is absorbed by the body and can interact with anticoagulants with serious consequences.

Denture disinfection is essential, and can be achieved by soaking the denture overnight in 0.2% chlorhexidine. This agent is effective against *C. albicans* (Budtz-Jorgensen and Bertram 1970). Alternatively a mild sodium hypochlorite solution can be just as effective, provided the dentures do not contain a resilient soft lining or metal baseplate. The dentures are soaked overnight in a denture dish of water containing a few drops of household bleach. In the morning, the patient must thoroughly rinse the dentures before placing them in the mouth.

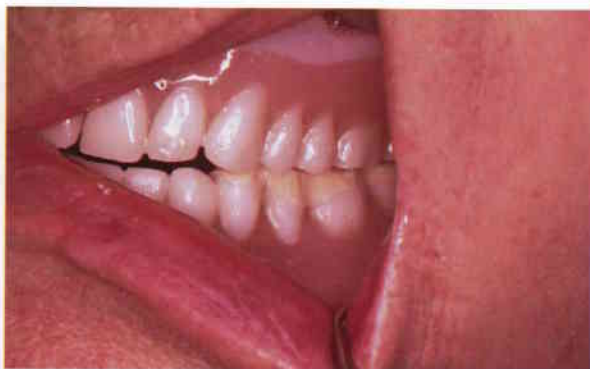### Treatment of Denture Stomatitis

Unsuccessful treatment of this chronic condition is common. Bergendal (1962) treated patients with denture stomatitis by providing denture hygiene, nutritional advice, new dentures, and surgical removal of hyperplastic tissue, but after 1 year a considerable number of patients showed relapse. The patient's existing dentures need to be adjusted prior to provision of replacement dentures. Treatment involves adjustment of the dentures to eliminate trauma either from a poorly fitting denture base or a premature occlusion. Tissue conditioning materials when applied to the fitting surface of the denture will improve the adaptation of the denture to the tissues. Tissue conditioner materials (e.g. Viscogel, manufactured by Dentsply Detrey, Weybridge, UK) are viscoelastic and reduce the occlusal load that is applied to the underlying mucosa, but patients complain that they are difficult to keep clean as food gets easily trapped in the surface. These materials quickly become hard and need to be replaced at weekly intervals. An alternative method of improving tissue adaptation is to reline the fitting surface of the upper denture with a hard chairside relining material (such as Kooliner, manufactured by GC America, Alsip, Ill., USA, or Tokuso Rebase, manufactured by the Tokuyama Corporation, Tokyo, Japan.). However, care is required to ensure that the dentures have sufficient freeway space, as applying material to the fitting surface may completely obliterate it.

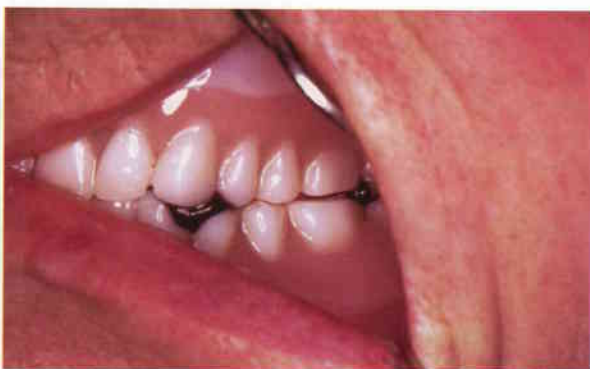### *Adjusting the Occlusion in Patients with Denture Stomatitis*

This may be achieved using articulating paper. Often the patient's dentures have become severely worn, and require restoration of their occlusion with self-curing acrylic. Usually an addition to the occlusal surface of 2–3 mm of acrylic will be sufficient (Fig. 1.4). The patient's upper denture teeth must be coated with a thin layer of petroleum jelly and the resin applied to the occlusal surface of the lower teeth. With the mandible fully retruded, the patient occludes gently into the resin for a few seconds. The resin is then removed from the patient's mouth and polymerized in water under pressure. The denture occlusion is checked with articulating paper, and the occlusal surface smoothed and polished.

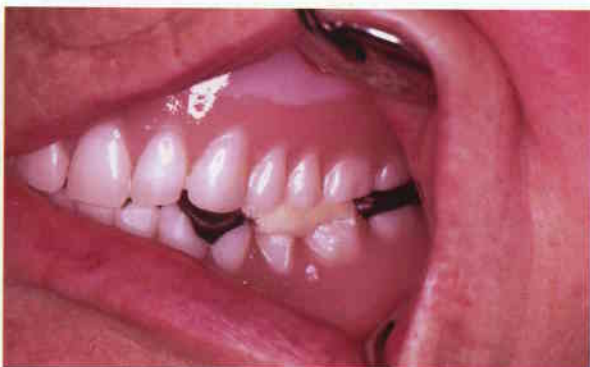**Fig. 1.4.** Excessive wear of the posterior acrylic teeth can be corrected by adding a layer of self-curing acrylic resin (maximum of 3–4 mm in thickness) to the lower molars. Petroleum jelly, smeared onto the upper molar teeth, allows the teeth to be separated when the acrylic has become polymerized



**Fig. 1.5.** The patient occludes into the warm composition to record the new occlusal vertical dimension



**Fig. 1.6.** Self-curing acrylic is placed on the lower molar teeth and the patient closes together. The impression compound maintains the correct occlusal vertical dimension as the acrylic hardens in the patient's mouth. The denture is removed and the acrylic fully cured, polished and returned to the patient



However, it may be difficult for the patient to apply the correct amount of light occlusal pressure. If the patient occludes into some warm compound placed on the occlusal surface of the lower canine and second molar teeth, a controlled amount of opening is achieved (Fig. 1.5, p. 11). The compound acts as an occlusal stop as the patient closes together into the acrylic (Fig. 1.6, p. 11). When the acrylic has cured the compound is removed and replaced by another mix of acrylic.

### ***Cleaning the Dentures in Patients with Denture Stomatitis***

Surveys of denture wearers have shown that most soak their dentures overnight in a solution of alkaline peroxide cleanser. This solution has some antibacterial and antifungal properties, but the effect is enhanced if the dentures are first mechanically cleaned to remove food debris and plaque. In patients with sufficient motivation, cleaning dentures with a brush and soap can be effective and there are no adverse effects on the dentures. Most elderly people do not know how to keep dentures clean (Hoad-Reddick et al. 1990) and methods that involve placing dentures in soaking solutions involve little physical effort.

Jagger and Harrison (1995) recommend placing dentures in a solution of alkaline hypochlorite for 20 min, rinsing them in water and then soaking them overnight in water. Acid cleansers, such as Denclen (Proctor and Gamble, Egham, UK) remove calculus and heavy stain. Dentures with resilient liners or metal reinforcement can be adversely affected by hypochlorite or acid solutions which should be avoided in these situations.

### ***Improving Tissue Adaptation in Patients with Denture Stomatitis: Technique for Chairside Reline***

Temporary relining or tissue conditioning can be carried out using Soft Liner (GC Corporation, Tokyo, Japan). The reline material is mixed according to the manufacturer's instructions and a thin layer applied to the clean fitting surface of the upper denture. The patient occludes gently in the retruded contact position, while the dentist applies functional movements to the periphery. This usually takes a few minutes. If used to treat denture stomatitis, this material should be replaced at weekly intervals until the condition is resolved.

If a nonresilient acrylic material is used where the patient has undercut residual ridges, it is important that the material is not left in the patient's mouth so long that it becomes hard and the denture cannot be removed. The denture is removed just as the material becomes rubbery, and further polymerization carried out in a hydroflask under pressure. The denture is trimmed, polished and returned to the patient.

## Resilient Lining Materials

After 1 year to 18 months, colonies of *C. albicans* can often be observed growing on the surface of lower resilient lining materials as white plaques. These resilient relining materials require replacement with fresh material.

## Other Soft Tissue Abnormalities

When a frenum extends to the residual ridge and the peripheral seal is compromised, poor denture retention can result (Fig. 1.7). In addition, excessive relief of a thick, fleshy frenum can make the denture prone to fracture in this region. Excision of frenal attachments is a relatively simple procedure that can do much to improve denture retention.

Tissue hyperplasia may result from an overextended denture periphery (Fig. 1.8). Reducing the denture extension, thereby relieving the chronic irritation, can reduce the size of the hyperplastic tissue. After 4–6 weeks a substantial reduction in the size of the tissue should have occurred, but if not, then surgery can be considered.

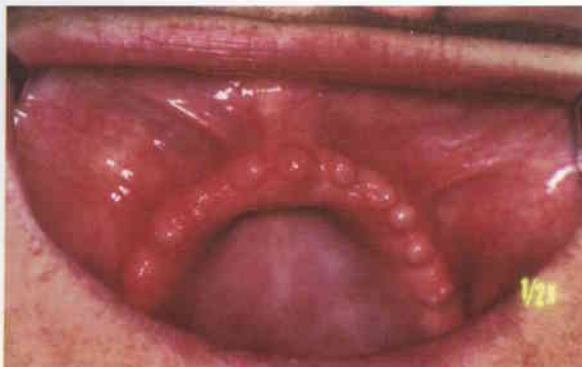
Fig. 1.7. Multiple, fleshy frenae are easily traumatized by the overextended denture flange. If extensively relieved, they can cause the denture to become loose and prone to fracture

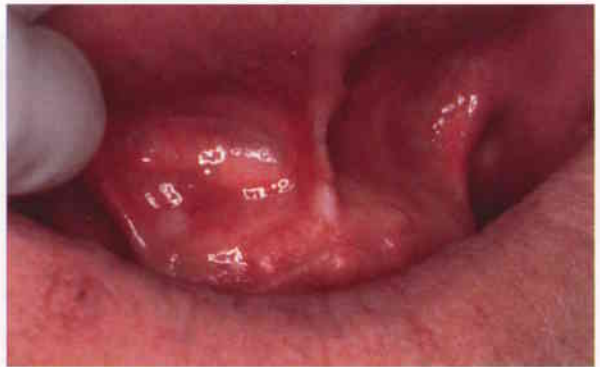
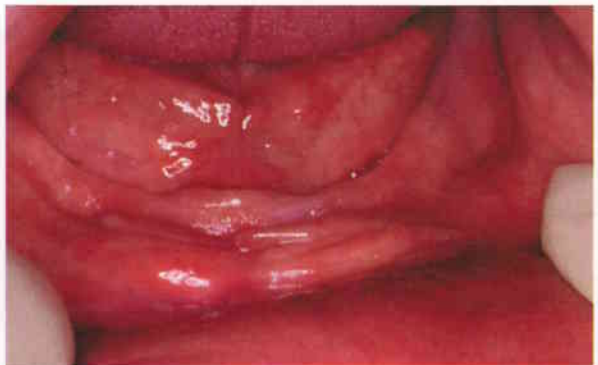
Fig. 1.8. A lower denture with an overextended labial flange can cause formation of hyperplastic tissue in the mandibular labial sulcus. Several folds of scar tissue are often formed. This occurs as a result of bone resorption and wear of the denture teeth causing the lower denture to move its position relative to the mandibular ridge







**Fig. 1.9.** Abnormal residual ridge contour resulting from the patient wearing a poorly fitting immediate denture for many years

Enlarged tuberosities can be fibrous or bony in nature. Where the tissue is hard bone, full extension of the denture into the undercut is not possible unless a resilient lining material is used. The bony tuberosity should be surgically reduced only when it impinges on the lower ridge and prevents optimal extension of the lower denture. As the maxillary sinus may extend into the tuberosity and complicate tuberosity reduction, a radiographic assessment is essential prior to any surgery.

If a socket-fitted immediate denture is inserted but not replaced for many years, the denture will become ill-fitting. Hyperplastic ridge tissue (Fig. 1.9) and an abnormally contoured residual ridge may result which can compromise the success of replacement dentures.

## Prognosis of Treatment

The patient should be given an explanation of the treatment required, if any, and the likelihood of success. Patients may have unrealistic expectations, especially about the ability of dentures to restore a youthful appearance, e.g. by eliminating wrinkling of the face. Even comparatively simple requests by patients to have more of the anterior teeth on the new denture visible can be problematic, as excessive overlap of the anterior teeth can cause excessive incisal guidance resulting in a lack of occlusal balance.

## References

- Barclay JK, Donaldson KI (1962) Panoramic radiography of the edentulous jaws – a survey of 100 patients. *N Z Dent J* 66:53–60
- Bergendal T (1962) Status and treatment of denture stomatitis patients: a 1-year follow-up study. *Scand J Dent Res* 90:227–238
- Budtz-Jorgensen E, Bertram U (1970) Denture stomatitis II. The effect of antifungal and prosthetic treatment. *Acta Odontol Scand* 28:283–304

- Burnett CA, Calwell E, Clifford TJ (1993) Effect of verbal and written education on denture wearing and cleansing habits. *Eur J Prosthodont Rest Dent* 2:79-83
- Cawood JI, Howell RA (1988) A classification of the edentulous jaws. *Int J Oral Maxillofac Surg* 17:232-236
- Davenport JC (1972) The denture surface. *Br Dent J* 133:101-105
- Fenton AH (1998) The decade of overdentures: 1970-1980. *J Prosthet Dent* 79:31-36
- Glass BJ, Seals RR Jr, Williams EO (1994) Common errors in panoramic radiography of edentulous patients. *J Prosthodont* 3:68-73
- Hoad-Reddick G, Grant AA, Griffiths CS (1990) Investigation into the cleanliness of dentures in an elderly population. *J Prosthet Dent* 64:48-52
- Jagger DC, Harrison A (1995) Denture cleansers - the best approach. *Br Dent J* 178:413-417
- Newton AV (1962) Denture sore mouth. *Br Dent J* 112:357-360
- Rushton VE, Horner K (1996) The use of panoramic radiology in dental practice. *J Dent* 24:185-201
- Samaranyake LP, McCourtie J, McFarlane TW (1980) Factors affecting the adherence of *Candida albicans* to acrylic surfaces in vitro. *Arch Oral Biol* 25:611-615
- Velkoff V (2000) Centenarians in the United States, 1990 and beyond. *Stat Bull Metrop Insur Co* 81:2-9
- Walker DM, Stafford GD, Huggett R, Newcombe RG (1981) The treatment of denture-induced stomatitis. Evaluation of two agents. *Br Dent J* 151:416-419
- Wilson J (1998) The aetiology, diagnosis and management of denture stomatitis. *Br Dent J* 185:380-384
- Witter DJ, van Palenstein Helderman WH, Creugers NH, Kayser AF (1999) The shortened dental arch concept and its implications for health care. *Community Dent Oral Epidemiol* 27:249-258

---

## 2 Impression Taking and Mucosal Loading

|                                                                                       |    |
|---------------------------------------------------------------------------------------|----|
| Anatomy of Mucosal Tissues .....                                                      | 18 |
| How Does Oral Mucosa Behave in Function? ...                                          | 18 |
| The Principles of Impression Procedures .....                                         | 19 |
| Impression Taking Procedures .....                                                    | 20 |
| The Mucostatic Impression Technique ...                                               | 20 |
| The Mucocompressive<br>Impression Technique .....                                     | 20 |
| The Selective Mucocompressive<br>Impression Technique .....                           | 21 |
| Disinfection Procedures .....                                                         | 21 |
| The Impression in the Maxillary Region .....                                          | 21 |
| The Primary Compound Impression .....                                                 | 21 |
| The Secondary Alginate<br>Maxillary Impression .....                                  | 22 |
| The Mandibular Impression .....                                                       | 25 |
| The Lower Compound Primary Impression                                                 | 25 |
| The Lower Special Tray Impression<br>Using Zinc Oxide/Eugenol Paste .....             | 26 |
| Selective-pressure Impression<br>for the Lower Ridge .....                            | 28 |
| The Upper Selective-pressure<br>Impression Technique .....                            | 28 |
| Occlusal Considerations with a Fibrous Ridge ..                                       | 30 |
| Should Load Be Deliberately Applied<br>to the Tissues During Impression Procedures? . | 31 |
| The Gagging Patient:<br>Are Impression Procedures Possible? .....                     | 31 |
| References .....                                                                      | 32 |



## Anatomy of Mucosal Tissues

Different areas of the oral mucosa vary in their capacity to sustain load because of their differing structure. For successful complete denture treatment, loading of the tissues must be reflected in the pressure-bearing capacity of the tissues. Where the denture-bearing mucosa is tightly bound down to the underlying bone, for example over the residual edentulous ridge, the tissue is called a mucoperiosteum. Usually there is a covering of keratinized or parakeratinized epithelium. A hard acrylic denture base easily traumatizes prominent areas of thin mucoperiosteum, for example over the maxillary canine eminence or over a thin atrophic lower ridge.

In other areas of the mouth the situation may be different. In the region of the posterior palatal junction of the upper denture, areas of differing compressibility occur. Close to the midline the mucosa is tightly bound to the underlying bone, more laterally the epithelium covers a layer of variable loose fatty and glandular tissue called the submucosa. The submucosa extends further forward along the length of the palate, laterally on either side of the midline where it contains the greater palatine nerve and blood vessels. This tissue is compressed by the posterior edge of the denture to form the postdam. Gentle pressure of the postdam of the denture on resilient palatal tissues is necessary to create close approximation of the denture in this area. The postdam should be cut into the cast, taking the compressibility of the submucosa into account.

If the patient has a strong gag reflex with denture wearing, positioning the postdam of the complete denture further anteriorly over the mucoperiosteum is not an option. This is because the inelastic nature of the palatal tissue in this region prevents an ideal posterior seal, with the result that denture retention is often compromised. One solution to this problem involves constructing a very thin, self-curing acrylic baseplate (without artificial teeth) that is extended to the posterior palatal vibrating line. The baseplate is maximally retentive because a postdam is incorporated and functional displacing forces are minimal. The patient is encouraged to wear the baseplate continuously for increasing lengths of time during the day. If a second, slightly anterior postdam is incorporated into the design, the baseplate can be reduced in size if the patient cannot become accustomed to the full extension.

## How Does Oral Mucosa Behave in Function?

The shape of the oral mucosa is constantly changing as dentures apply intermittent loads throughout the day. Oral mucosa behaves in a viscoelastic manner. If a constant load is applied, there is a sudden elastic displacement, followed by a slower "creep" phase where tissue fluid is expressed from the tissues. If the load is released, immediate elastic recovery of the shape of the tissues is followed by a delayed recovery lasting many hours. Where an impression of the minimally dis-

placed oral tissues is desirable, the patient should be encouraged not to wear dentures for several hours prior to impression taking.

## The Principles of Impression Procedures

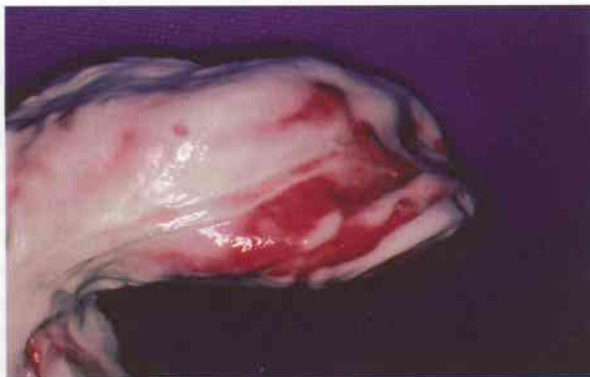For complete dentures, the vast majority of general dental practitioners use only irreversible hydrocolloid for primary impressions (Hyde and McCord 1999). However, this material does need to be supported in a stock tray with impression compound in order to achieve maximal extension. Impression compound is a thermoplastic material which can be used alone in the taking of preliminary impressions. Whether compound is used alone or supporting alginate, there is a tendency for these viscous materials to distend the sulcus. Therefore, vigorous border moulding of the impression material is essential.

Where the patient's residual mandibular ridge is very resorbed it can be difficult to distinguish the ridge from the sulcus when using impression compound. This will complicate construction of the special tray, giving rise to over- or underextension of the periphery. To assist the technician to visualize the residual ridge crest and sulcus on the primary cast, the dentist can modify the primary compound impression by applying an alginate-wash impression (Fig. 2.1). Fixative is applied to the dried compound impression surface and a thin, fluid mix of alginate applied on top.

The alginate/compound impression is positioned in the patient's mouth, border-moulded and removed when set. Using an indelible pencil, the dentist must mark on the primary impression, the extension required for the special tray. This will be transferred to the primary cast and assist the technician in constructing the special tray.

The primary impressions are cast in plaster and a special tray constructed for the definitive secondary impressions at the next clinical visit, when alginate is to be used. The special tray is constructed using a spacer thickness of 3 mm. The viscosity of alginate varies with the different brands and is also affected by the

Fig. 2.1. Applying a thin wash of alginate over the compound impression assists in delineating the residual ridge. Impression compound may not provide good surface detail, and where the residual ridge is resorbed, this technique is useful for distinguishing the crest of the ridge from the sulcus



water-to-powder ratio. Care should be taken not to use too much water as a runnier mix produces underextension.

Alginate is popular because of its excellent properties. It is an elastic material and can record reasonable undercut. The final impression records fine detail and is compatible with casting materials such as plaster and stone. Alginate impressions must be cast up quickly as they dry out and distort with time. This effect is reduced by keeping the impression material wrapped in damp muslin in a plastic bag prior to casting up. Materials such as plaster of Paris are more dimensionally accurate and stable, but patients tolerate alginate more easily.

## Impression Taking Procedures

There are three principal approaches to impression taking: the mucostatic, mucocompressive, and the selective mucocompressive techniques.

### *The Mucostatic Impression Technique*

The objective of this technique is to obtain an impression of the tissues in their resting state. The dentist uses a less viscous impression material with minimal application of pressure on the impression tray. Plaster of Paris or alginate are the impression materials of choice. The denture then fits accurately on the tissues at rest, a situation that prevails for most of the time that the patient is wearing the denture. During mastication, the denture will tend to rotate on the most incompressible areas, e.g. torus palatinus, and may lose retention. The adverse effects can be reduced by placing tin foil (of about 0.5 mm thickness) on those areas of the cast where incompressible tissue is present prior to processing the denture.

### *The Mucocompressive Impression Technique*

With mucocompression, the denture-bearing tissues are compressed during impression taking and will be subsequently compressed during denture wearing. Because of the viscoelasticity of the oral soft tissues they will remain compressed for many hours after function (Lytle 1959). When the denture is processed, it will therefore be maximally retentive during function when the fitting surface has its closest contact with the tissues. The denture will have reduced retention when it is not under load, e.g. when the patient is at rest or speaking. Pressure can be manually applied to the oral tissues using a high-viscosity impression material, e.g. impression compound or by using a close-fitting tray. Alternatively, the denture bearing tissues can be compressed using a closed-mouth impression technique. With this method, load is applied to the tissues using wax record rims with acrylic baseplates, instead of using impression

trays. Zinc oxide/eugenol paste is applied to the fitting surface of the rims and the patient applies occlusal load.

Several problems can occur with this technique. If the occlusal pressure is excessive, then the fitting surface of the baseplate may be visible through the impression over a large area. Occlusal load will be concentrated in these areas. Secondly, the occlusion must be even, otherwise excessive mucosal displacement may occur unilaterally.

### ***The Selective Mucocompressive Impression Technique***

In this technique, only selected areas of the tissues are subjected to compressive forces. The technique is described later in this chapter.

## **Disinfection Procedures**

Rinsing impressions under the tap will remove surface debris and mucin, but does not provide adequate disinfection of impressions. Haz-tabs, manufactured by Guest Medical (Edenbridge, Kent, UK), consist of sodium dichloroisocyanurate dihydrate. One tablet dissolved in 2.5 l of water provides an appropriate disinfecting solution with a concentration of 1000 parts per million of available chlorine.

## **The Impression in the Maxillary Region**

When taking maxillary impressions, the dentist stands behind and slightly to one side of the patient who should be positioned so that the maxilla is level with the dentist's elbow. In this position, the dentist can firmly control the impression tray and locate it centrally in the patient's mouth with the handle in line with the patient's nose.

### ***The Primary Compound Impression***

An upper edentulous stock tray is chosen which is a loose fit, but covers the available denture-bearing area. Disposable plastic trays are commonly available for complete denture construction but they rarely accurately fit the ridge (Ogden et al. 1994). A primary impression has to be taken so that a special tray can be constructed to take an accurate final impression. Low fusing impression compound can be used to construct the primary impression because it can be applied to the impression, or removed, until the operator is satisfied with the retention of the impression. Impression compound does not give an accurate impression surface,

but it registers the extent of sulcus and denture extension. It should not be used where the ridge is displaceable; in these circumstances, fluid alginate or plaster of Paris are preferable alternative primary impression materials.

Impression compound is heated to 60°C in a water bath and applied to the dry impression tray. Shaping the compound to the approximate shape of the tissues prior to inserting the tray in the mouth assists in locating the tray accurately. The surface of the material is flamed and tempered in hot water. The loaded tray is then inserted and positioned to cover the maxillary tuberosities and pterygoid hamulus regions and the front of the tray is raised with the excess material extruding into the sulcus. The upper lip is elevated and then released to cover the compound, and border moulding carried out. This is where the fingers and thumb manipulate the lips and cheeks to simulate functional movements. An index finger may be necessary to mould the compound into the distobuccal region of the sulcus, with the patient's mouth half open. When the impression compound has cooled sufficiently, it is removed from the mouth and examined. Impression compound is a viscous material and will readily distend the sulcus, so the impression should be adjusted with a wax knife so that it is only minimally overextended. Frenal attachments should be clearly visible. The periphery of the impression can then be warmed, and placed back in the mouth for repeat border moulding. The anterior flange should be no more than 3 mm in width, and rounded in contour.

The posterior flange is warmed, tempered in hot water and placed in the patient's mouth. The patient, moving the mandible from side to side, moulds the distobuccal region of the upper impression with the coronoid process. The patient should also open and close the mouth to allow the medial pterygoid muscle to mould the compound. Where the force required to displace the impression is minimal, tracing stick compound can be applied to the impression in the region of the postdam. The full width and height of the sulcus is marked with a wax pencil on the impression periphery. The impression is disinfected and poured in plaster.

The set cast can be removed from the compound impression by soaking in water at 60°C for 5 min. The tray and compound are then peeled away from the primary cast.

An upper primary impression taken using impression compound is shown in Fig. 2.2.

### ***The Secondary Alginate Maxillary Impression***

A special tray is constructed on the primary cast from light-cured acrylic resin. Trays made from this material are strong, but brittle, and break easily if dropped. However, they are quickly and easily constructed. They should be 3 mm spaced, and cover the available denture bearing area. The upper tray should extend up to a line between the hamular notches. Alginate does tend to displace the vestibular



Fig. 2.2. An upper primary impression taken using impression compound

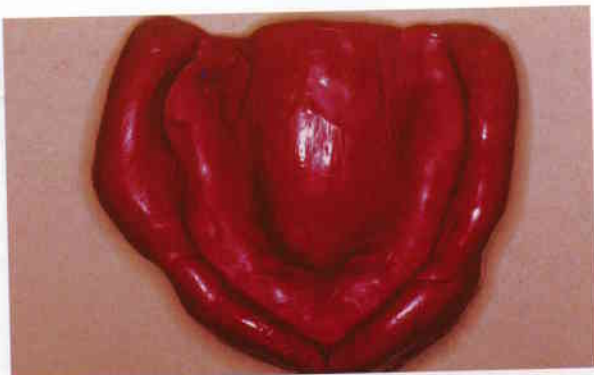
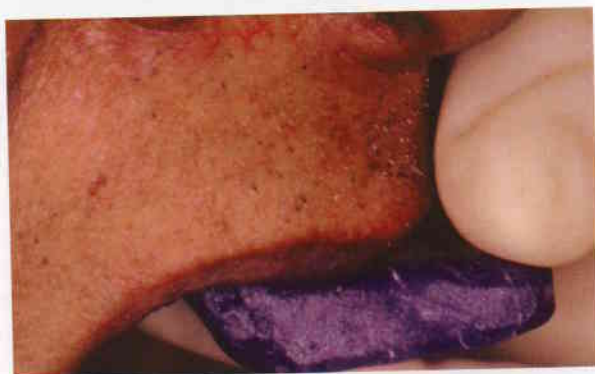
Fig. 2.3. Although the stepped handle is convenient, it can interfere with the correct border moulding of the impression



tissues, especially if of a viscous consistency (Lamers 1991). Therefore, the periphery of the special tray should be finished 2–3 mm short of the anticipated border of the denture to allow functional movements of the peripheral tissues and correct border moulding of the alginate. The tray extension should be checked carefully on the cast, and areas of overextension reduced.

A central, vertical stub handle should support the upper lip. Therefore the handle of the special tray should occupy the position occupied by the upper natural incisor teeth (Morris 1997). Stepped handles should be avoided as they can interfere with the upper lip when border moulding (Fig. 2.3).

The tray is disinfected, and then washed under running tap water. Anterior wax stops are attached to the tray in the premolar region on both sides. Overextended areas where the tray, for example, impinges on frenal attachments should be relieved generously. Posteriorly, tracing stick compound is applied to the special tray to cover the vibrating line (the junction between the mobile and immobile parts of the palate), hamular notches and buccal to the tuberosity regions (Fig. 2.4 above). Other areas of underextension can be corrected by adding tracing stick compound to the tray. The tray is frequently underextended lateral to the tuberosity. The retention of the tray can be assessed, and if satisfactory, the

Fig. 2.2. An upper primary impression taken using impression compound

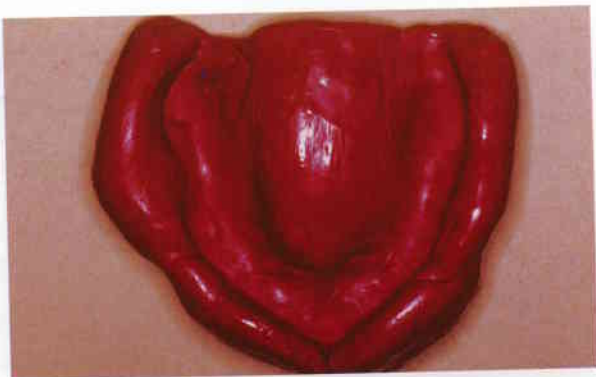
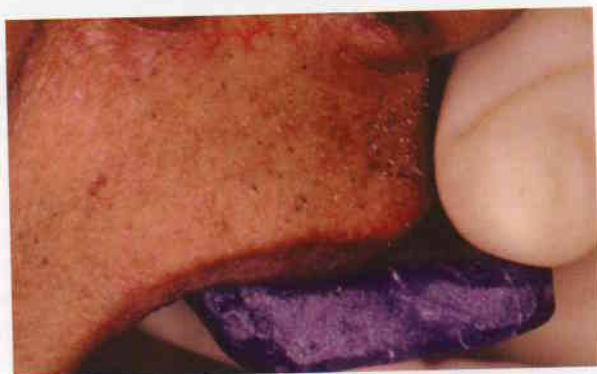
Fig. 2.3. Although the stepped handle is convenient, it can interfere with the correct border moulding of the impression



tissues, especially if of a viscous consistency (Lamers 1991). Therefore, the periphery of the special tray should be finished 2–3 mm short of the anticipated border of the denture to allow functional movements of the peripheral tissues and correct border moulding of the alginate. The tray extension should be checked carefully on the cast, and areas of overextension reduced.

A central, vertical stub handle should support the upper lip. Therefore the handle of the special tray should occupy the position occupied by the upper natural incisor teeth (Morris 1997). Stepped handles should be avoided as they can interfere with the upper lip when border moulding (Fig. 2.3).

The tray is disinfected, and then washed under running tap water. Anterior wax stops are attached to the tray in the premolar region on both sides. Overextended areas where the tray, for example, impinges on frenal attachments should be relieved generously. Posteriorly, tracing stick compound is applied to the special tray to cover the vibrating line (the junction between the mobile and immobile parts of the palate), hamular notches and buccal to the tuberosity regions (Fig. 2.4 above). Other areas of underextension can be corrected by adding tracing stick compound to the tray. The tray is frequently underextended lateral to the tuberosity. The retention of the tray can be assessed, and if satisfactory, the

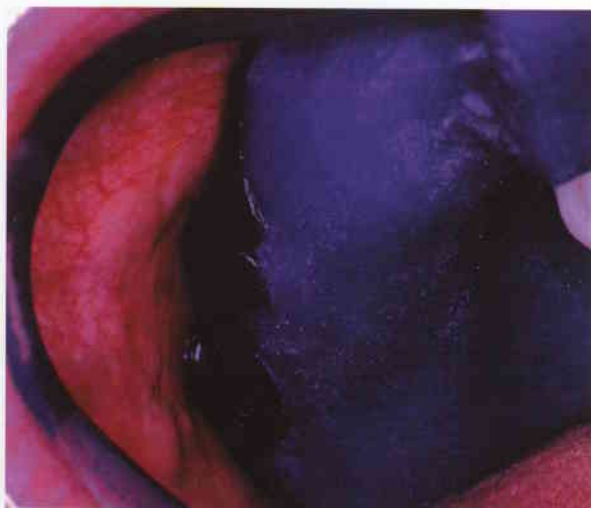
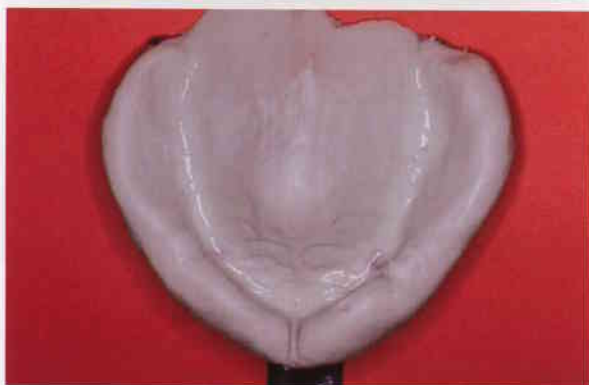
Fig. 2.4. *Above:* Obtaining an impression with the correct width of the sulcus allows the denture to develop a peripheral seal with the cheeks and lips. *Below:* The completed alginate impression is examined for defects



tray is perforated, washed and dried. A thin layer of adhesive is applied to the fitting surface, the periphery, and about 3 mm of the buccal surface of the tray, and allowed to dry. Excessive application of adhesive can cause pooling of the liquid and a lack of adhesion.

The mixed alginate is applied to the tray, which is rotated into place. The back edge of the impression is located first and then the front of the impression positioned. With the patient's mouth half-open, the tray can be located more easily and the lips and cheeks are in a more relaxed position to take part in border moulding. The excess alginate flows forward into the labial sulcus. One hand stabilizes the tray, while the other carries out border moulding procedures. When the alginate has set, the impression is removed by lifting the cheeks on one side and simultaneously rotating the tray away from the tissues. The patient is instructed to rinse the mouth. The impression is examined to ensure that the anatomical features have been recorded (Fig. 2.4 below).



The alginate impression is rinsed in water and disinfected. The impression is wrapped in damp muslin and stored in a sealed bag for transport to the laboratory. The instructions to the laboratory should request the impressions be cast in dental stone, and wax occlusal rims constructed with either a shellac or light-cured acrylic baseplate.

## The Mandibular Impression

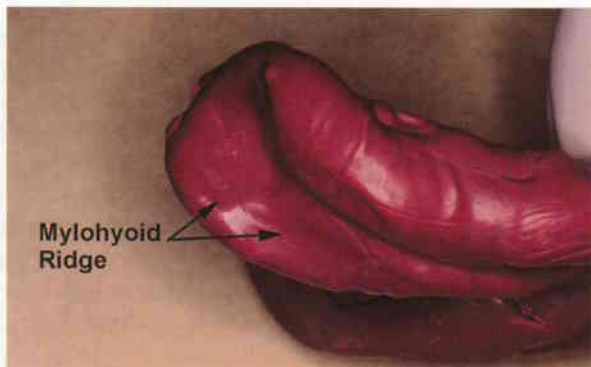
For the lower impression, the dentist should stand in front and to one side of the patient with the patient's mandible level with the dentist's upper arm.

### *The Lower Compound Primary Impression*

Using a stock tray and impression compound or alginate, an overextended impression of the lower ridge is often produced. With severe mandibular ridge resorption, the genial tubercles remain prominent because of the attachment of the genioglossus muscle. Often in these cases, the tray rocks about the central bony prominence. Impression compound has the advantage that it can be extended into the distolingual area more easily (Fig. 2.5), and is therefore the material of choice. Retromylohyoid extension is important in the stability of the lower denture (Jooste and Thomas 1992), but can be difficult for patients to tolerate.

A slightly oversized stock tray is chosen to ensure that the residual ridges and retromolar pad are covered. Softened impression compound is applied to the stock tray and, after flaming and tempering in hot water, the compound is inserted in the patient's mouth. The tray is rotated into position and placed vertically onto the residual ridge. The cheeks may have to be gently pulled outwards to avoid them being trapped by the compound. The patient is instructed to raise the tongue to the upper lip as the tray is pressed gently onto the ridges. The forefingers support the tray in place, while the thumbs rest under the lower border of

**Fig. 2.5.** A lower primary impression extended into the distolingual sulcus. The viscous nature of impression compound favours a successful result. The periphery of the denture should extend slightly below the mylohyoid ridge



the mandible to provide support. The tongue carries out border moulding lingually by wiping the upper lip and extending alternately into each cheek. Border moulding is carried out labially and buccally by gentle manipulation of the cheeks with one hand, while the other hand stabilizes the position of the tray. The compound impression is removed from the patient's mouth when it has cooled sufficiently. The impression is examined to ensure that frenae, sulcus, retromolar pads, mylohyoid ridges and residual ridges are accurately recorded. Areas of gross overextension are removed and the impression is flamed, tempered and re-applied into the patient's mouth, where border moulding is repeated.

Where resorption has been particularly severe, the residual ridge blends imperceptibly into the sulcular tissues. With severe ridge resorption anteriorly, the labial sulcus can sometimes seem difficult to identify as it merges into the mentalis muscle. This can make construction of the special tray difficult, as the correct peripheral extension can be indefinable. A thin wash of zinc oxide/eugenol paste applied to the primary compound impression can outline the sulcus by providing more surface detail. Alternatively, a fluid mix of alginate can be used.

### *The Lower Special Tray Impression Using Zinc Oxide/Eugenol Paste*

The primary impression is cast in plaster and a lower close-fitting special tray constructed in light-cured dimethacrylate resin. A vertical stub handle is positioned centrally, to locate the tray and remove it following completion of the impression-taking procedure. Additional stub handles can be included in the premolar region of the tray, to be used as finger rests while the impression material sets. The lower special tray is underextended by 3 mm so that a sufficient quantity of tracing stick compound can be applied to the periphery of the tray and adapted to the functional shape of the sulcus. However, before adding the compound, the extension of the tray in the mouth is checked by manipulating the lips and cheeks and any overextension removed. The patient protrudes the tongue to touch the upper lip and if the tray is displaced, the distolingual region of the tray in the retromylohyoid space is reduced. Any other areas of overextension are removed and the borders are smoothed.

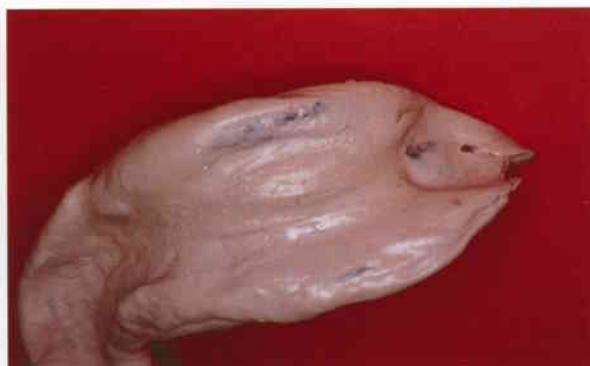
Tracing stick compound is heated and applied to the tray periphery. The compound is tempered in hot water, placed in the mouth and border-moulded with functional movements of the patient's lips and cheeks. The peripheral border extension of the lower tray is modified with tracing stick compound (Fig. 2.6). The lower tray is designed to support the lips and cheeks in the same way as the completed denture. This is accomplished by adding tracing stick compound to the labial and buccal surface of the tray to record the full width of the sulcus. The buccinator muscle attaches to the external oblique ridge of the mandible and limits the extension of the impression in this region.

The most difficult region to record accurately, the lingual extension, is modified in thirds. Tracing stick compound is applied to the retromylohyoid area on

Fig. 2.6. Stock trays are usually deficient in their distolingual extension. Therefore correct adaptation of the special tray requires modification with impression compound in this region



Fig. 2.7. The distolingual extension of the lower secondary impression should extend over the retromolar pad and about 3 mm below the mylohyoid ridge. A thick lingual flange to the denture will allow the denture to be displaced by the tongue



the right side, the left side and finally the anterior lingual region. Each time the compound is moulded by the action of the tongue, which wipes the upper lip. Impression compound is added to the tray labially and buccally, and is moulded by the cheeks and lips. The correct amount of directed movement of the tissues to obtain a peripheral seal can be difficult to determine.

The tray covers the retromolar pad and extends into the retromylohyoid space, where its posterolingual extension is limited by the palatoglossal muscle. This muscle forms the anterior pillar of the fauces. The floor of the mouth moves upward during function due to contraction of the mylohyoid muscle, therefore the lingual border has a resting and active level. The lingual border extension of the lower tray can be checked functionally by adding increments of impression compound, and visually by ensuring the tray periphery extends towards the base of the tongue. When the patient relaxes the tongue, it remains in light contact with the periphery of the tray and is retentive. However, if the tongue is retracted habitually to guard the pharynx, then in this position the tray is unretentive.

Petrolatum (Vaseline) is applied to the patient's lips to allow easy removal of the zinc oxide paste. Having dried the tray, a thin layer of zinc oxide/eugenol

paste is added. Care should be taken to cover the entire periphery with paste prior to insertion of the tray in the patient's mouth to ensure sufficient material on all borders. The tray and impression material are inserted, and the lips and cheeks manipulated to mould the peripheral border of the impression. The forefingers rest on the vertical stub handles to prevent distortion of the impression, and the thumbs are placed under the lower border of the mandible to provide support. Correctly extending the impression in the distolingual area is necessary for good denture retention (Fig. 2.7).

### Selective-pressure Impression for the Lower Ridge

Gentle palpation of the crest of the residual ridge can sometimes elicit pain due to an irregular shape to the underlying bone. The crest of the residual ridge undergoes continuous resorption and histologically can resemble a coarse cancellous bone. Often a mobile fibrous remnant is present over the crest of the residual ridge. The tissues lateral to the crest of the ridge and in the sulcus may be better able to tolerate applied occlusal load. The selective pressure impression technique records loading of the peripheral tissues.

An alginate impression of the lower jaw is taken in an edentulous stock tray, modified to be fully extended. A fluid mix of alginate avoids tissue distortion. This impression is cast in laboratory plaster, and a 3-mm spaced special tray is constructed in light-cured acrylic, as previously described. An impression of the cast is now taken using impression compound in the special tray to produce a layer about 3 mm thick. On removal from the cast, the periphery of the compound is heated and the border moulded in the patient's mouth. The impression compound in the centre of the tray over the crest of the ridge is removed and the tray perforated in this region. The tray is washed and dried. Zinc oxide/eugenol is applied over the whole fitting surface of the tray, which is inserted into the patient's mouth. Zinc oxide/eugenol exudes from the holes on the top of the tray, thus applying reduced pressure in this area. It may not be possible to incorporate stub handles on the ridge crest of the tray as they may interfere with the provision of the perforations. The border-moulding procedures are carried out and when the zinc oxide/eugenol impression material has set, the impression is removed from the mouth and disinfected. It is cast in dental stone.

During mastication, with lower dentures constructed using the selective pressure impression technique, occlusal load is greater over the peripheral tissues and less over the crest of the ridge.

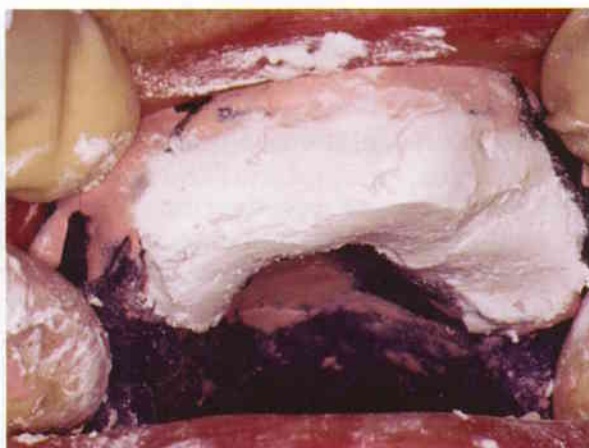
### The Upper Selective-pressure Impression Technique

This impression technique is used when the upper ridge is flabby in one area, usually the anterior region, but firm elsewhere. A fluid alginate impression is tak-

Fig. 2.8. An anterior window over the flabby fibrous ridge is provided in the tray

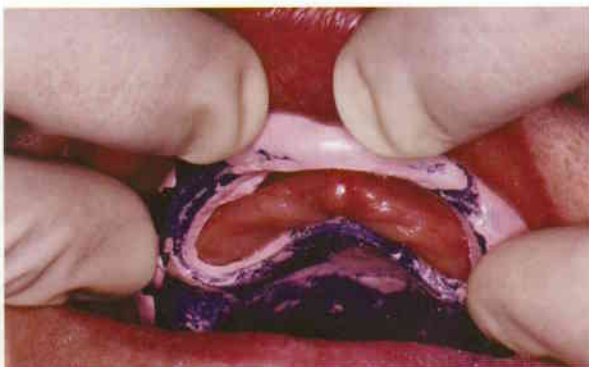

Fig. 2.9. A thin mix of plaster of Paris is applied to the fibrous ridge protruding through the window. When the plaster has set, the tray is removed. A separating fluid is applied to the anterior plaster and the impression cast up in plaster/stone



en of the tissues and a plaster cast produced. A 2-mm spaced special tray is constructed on the cast, and made 3 mm underextended from the sulcus. The tray is used to obtain a compound impression of the plaster cast, but the cast must be soaked in cold water for 5 min so that the compound can be removed easily from the cast. The periphery of the cast is border-moulded in the mouth to correct the peripheral extension. The compound covering the firm area of the palate is flamed and tempered in hot water, and then reinserted into the patient's mouth. The firm tissue is compressed and the flabby tissue remains undistorted, providing maximum support for the denture during function. To improve the surface detail, the compound is coated with a thin layer of zinc oxide/eugenol impression paste and inserted in the patient's mouth. Border moulding is carried out, and when the paste has set, the impression is removed from the patient's mouth.

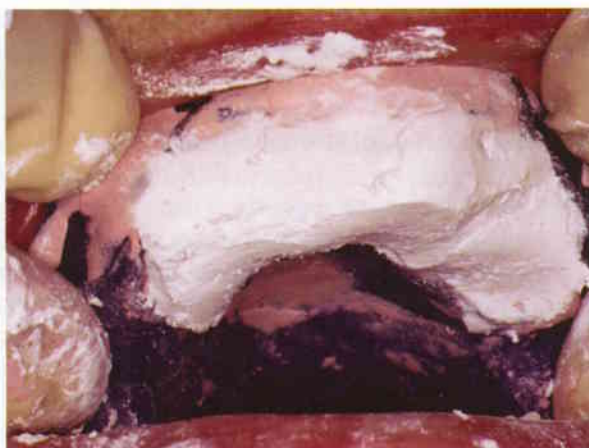
Watson (1970) described a selective mucocompressive technique for the fibrous maxillary ridge. He recommended taking a primary impression in plaster



Fig. 2.8. An anterior window over the flabby fibrous ridge is provided in the tray

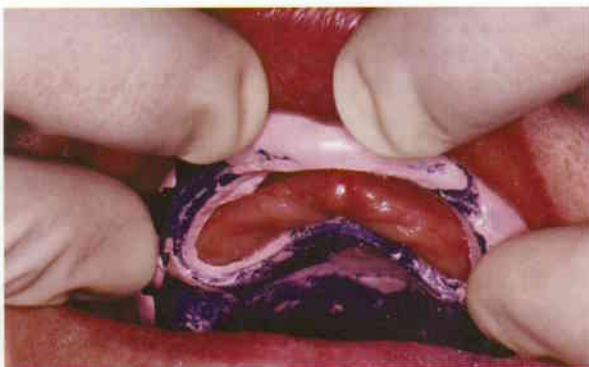

Fig. 2.9. A thin mix of plaster of Paris is applied to the fibrous ridge protruding through the window. When the plaster has set, the tray is removed. A separating fluid is applied to the anterior plaster and the impression cast up in plaster/stone



en of the tissues and a plaster cast produced. A 2-mm spaced special tray is constructed on the cast, and made 3 mm underextended from the sulcus. The tray is used to obtain a compound impression of the plaster cast, but the cast must be soaked in cold water for 5 min so that the compound can be removed easily from the cast. The periphery of the cast is border-moulded in the mouth to correct the peripheral extension. The compound covering the firm area of the palate is flamed and tempered in hot water, and then reinserted into the patient's mouth. The firm tissue is compressed and the flabby tissue remains undistorted, providing maximum support for the denture during function. To improve the surface detail, the compound is coated with a thin layer of zinc oxide/eugenol impression paste and inserted in the patient's mouth. Border moulding is carried out, and when the paste has set, the impression is removed from the patient's mouth.

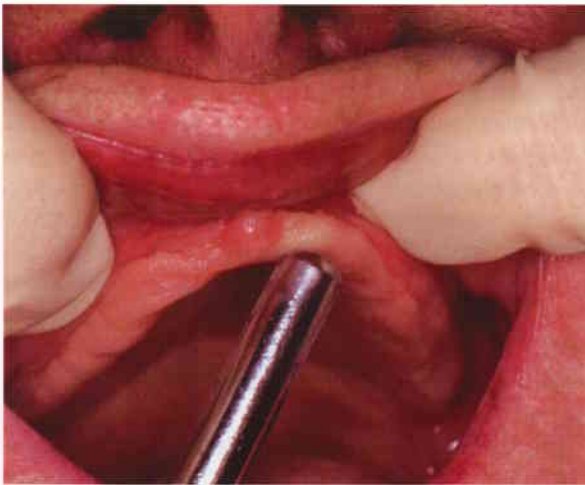
Watson (1970) described a selective mucocompressive technique for the fibrous maxillary ridge. He recommended taking a primary impression in plaster

of Paris, and constructing on the cast a close-fitting special tray with the mobile anterior tissues left exposed. A window is cut out of the tray over the flabby tissue. The upper tray is constructed of light-cured acrylic and handles are placed in the premolar area to avoid the open window (Smith et al. 1999). The special tray is border-moulded with tracing stick compound. Zinc oxide/eugenol paste is applied to the tray which is then seated in the patient's mouth (Fig. 2.8, p. 29). When set, a thin mix of plaster of Paris is applied to the fibrous ridge and covers the open window part of the tray (Fig. 2.9, p. 29). The impression is removed and cast in dental stone.

Selective pressure impressions should be cast up in dental stone and clear heat-cured acrylic baseplates constructed. Wax record rims are built on the baseplate. Any blanching of the underlying tissues can be observed clinically, and the baseplates adjusted if necessary. Unfortunately, if utilized in the final denture construction, these acrylic bases undergo warping as stresses are released during further polymerization of the dentures.

### Occlusal Considerations with a Fibrous Ridge

With a mobile, fibrous upper ridge there is a tendency for the upper occlusal rim or denture to rotate upwards during occlusion (Fig. 2.10). The retruded contact position should be recorded with minimal occlusal pressure. In the finished denture, intercuspation of the teeth will then assist in preventing rotation as load is applied. However, if any position other than the retruded contact position is recorded or heavy occlusal pressure is utilized, tilting of the base will inevitably occur.



**Fig. 2.10.** The fibrous ridge provides poor support for the denture as it is easily displaced



## Should Load Be Deliberately Applied to the Tissues During Impression Procedures?

Tissue loading tends to apply an unknown load to the tissues in a poorly controlled manner. With impression techniques that apply load, the initial retention of the dentures is good, but is soon lost possibly due to tissue changes. Whether these changes lead to ridge resorption is unknown. Distorted tissues will tend to rebound and cause loss of denture retention.

Most impression techniques therefore avoid the application of uncontrolled load to the tissues. For example, in the technique described by Klein and Broner (1985), a clear acrylic special tray adjusted to avoid any pressure is used. The special tray is close-fitting and vented with holes to avoid any hydraulic pressure of the impression material compressing the tissues. Zinc oxide/eugenol is the impression material of choice. The advantage of this technique is that blanching of the tissues can be observed directly prior to applying the impression material, and localized tissue distortion can be corrected.

## The Gagging Patient: Are Impression Procedures Possible?

Numerous methods including the use of hypnosis, sedatives, and topical local anaesthetics (Fleece et al. 1988) have been used to allow impression taking in the gagging patient. Friedman and Weintraub (1995) found that applying ordinary table salt to the tip of the tongue allows impression taking. They suppose that the afferent sensory input from the taste buds in the anterior part of the tongue in some way inhibits the gag reflex. The manner of the dentist, by relaxing the patient, is of vital importance in minimizing gagging. Many authors recommend some modification of the patient's breathing pattern to suppress gagging. Hoad-Reddick (1986) have recommended that patients practice deep, rhythmic breathing for 2 weeks at home so that they can adopt self-hypnosis during the subsequent denture construction procedures. Gagging is a reflex that is integrated in the medulla oblongata. Exaggerated breathing movements may inhibit the reflex, perhaps by inducing apnoea. Animal experiments have shown that inducing apnoea may inhibit retching (Chaffe et al. 1970).

Severe reduction in the posterior extension of the upper maxillary denture is doomed to failure. The resulting poorly retained upper denture drops onto the tongue and immediately induces the retch reflex. A very thin, upper acrylic baseplate (or training plate) can often be worn if fully extended (Hoad-Reddick, 1986; Singer 1973). As well as the normal postdam position, a slightly more anterior postdam than normal should also be incorporated to allow some adjustment of the posterior edge where necessary. The dentist is then able to reduce the posterior extension to some extent without loss of retention of the appliance. This appliance has the effect of habituating the patient to the feel of the denture in the mouth, prior to definitive denture construction.

## References

- Chaffe RB, Zabara J, Tansy MF (1970) Suppression of the gag reflex by exaggerated respiratory movements. *J Dent Res* 49:572-575
- Fleece L, Linton P, Dudley B (1988) Rapid elimination of a hyperactive gag reflex. *J Prosthet Dent* 60:415-417
- Friedman MH, Weintraub MI (1995) Temporary elimination of gag reflex for dental procedures. *J Prosthet Dent* 73:319
- Hoad-Reddick G (1986) Gagging: a chairside approach to control. *Br Dent J* 161:174-176
- Hyde TP, McCord JF (1999) Survey of prosthodontic impression procedures for complete dentures in general dental practice in the United Kingdom. *J Prosthet Dent* 81:259-299
- Jooste CH, Thomas CJ (1992) The influence of the retromylohyoid extension in mandibular complete denture stability. *Int J Prosthodont* 5:34-38
- Klein IE, Broner AS (1985) Complete denture secondary impression technique to minimize distortion of ridge and border tissues. *J Prosthet Dent* 54:660-664
- Lamers EM (1991) Complete denture final impression trays: a method of delineating borders. *J Prosthet Dent* 65:598-599
- Lytle RB (1959) Complete denture construction based on a study of the deformation of the underlying soft tissues. *J Prosthet Dent* 9:539-551
- Morris JC (1997) Handles on custom trays for complete master impressions. *J Prosthet Dent* 78:331
- Ogden AR, Siddiqui AA, Basker RM (1994) Disposable trays for complete denture construction; a dimensional study of a type frequently used in the U.K. and its suitability for the edentulous population. *Br Dent J* 176:303-309
- Singer I (1973) The marble technique: a method for treating the "hopeless gagger" for complete dentures. *J Prosthet Dent* 29:146-150
- Smith PW, Richmond R, McCord JF (1999) The design and use of special trays in prosthodontics: guidelines to improve clinical effectiveness. *Br Dent J* 187:423-426
- Watson RM (1970) Impression technique for maxillary fibrous ridge. *Br Dent J* 128:552

The buccal cusps of the mandibular teeth on the left side (balancing side) remain in contact with the maxillary teeth by contacting the palatal cusps. The teeth on the working side intercusate and the cusps occlude with flat surfaces on the opposing teeth (Nairn 1973). Cusps do not ride over opposing high-cusped surfaces on the working side. Little or no jaw separation is therefore observed on the working side.

Where premature occlusion exists on the working side, preventing even contact with teeth on the balancing side, then the occlusal surfaces of the working side are adjusted. It follows that the relevant buccal cusps of the upper teeth and the lingual cusps of the lower teeth should be shortened (the BULL rule). In this way there is little or no decrease in occlusal vertical dimension of the dentures.

With the semiadjustable articulators, it is possible to record the patient's individual condylar guidance using protrusive wax records. An alternative explanation for an absence of balancing side contacts in the patient's mouth may result from too-low an articulator condylar guidance setting on that side. In patients, the angle of the condylar path to the horizontal varies in the range 15–66° (Aull 1965). Therefore, if the patient's condylar path inclination is steeper than the condylar guidance, the balancing side molar teeth are separated in the patient's mouth (Jordan 1978).

Premature occlusal contacts on the balancing side can be difficult for patients to manage, as they find it difficult to obtain occlusal contact on the working side. Further protrusion of the condyle on the balancing side by the patient fails to improve the occlusion on the working side. However, by reducing the appropriate buccal cusp inclines of the lower teeth on the balancing side, the dentist can restore occlusal balance. Alternatively, premature contact on the balancing side can result from too-great a condylar guidance on the articulator and the setting of the posterior teeth with a steep lateral cusp height. If the condylar path inclination of the patient is shallow, then premature contact on the balancing side ensues (Jordan 1978).

As the lips lose muscle tone with age, many patients request increased lip support and more visible teeth. Increasing the overbite (or vertical overlap of the anterior teeth) would increase the incisal angle, which would cause a premature occlusion in protrusion. If occlusal balance is to be preserved a steeper posterior cusp height or compensating curve will be required. However, posterior teeth with high cusp angles (30° or more) tend to transmit more lateral loads to the residual ridge, which may cause instability. Therefore, it is more effective to set the upper anterior teeth further forward providing increased lip support, rather than increasing the overbite. With the upper teeth further forward, the effect on the upper lip is to lift it and make it appear shorter.

Errors in protrusive balance will be discussed in relation to setting the anterior teeth at the try-in. Adjusting the finished denture by reducing the length of the teeth can be detrimental to the aesthetics.

## Clinical Determination of the Jaw Relationship

Occlusal rims are used to determine the tooth position, occlusal vertical height and horizontal jaw relationship, and transfer this recording to the laboratory. Using this, together with the detailed written instructions provided, the technician can set the artificial teeth in the correct position. However, increasing numbers of dental surgeons are setting the anterior teeth into the wax record blocks at the chairside themselves, following completion of the jaw registration stage. With practice, this can be done quickly and has the advantage that the patient is present for discussion about their appearance while the teeth are positioned. The patient feels more involved in the denture-making process and therefore more likely to accept the new dentures.

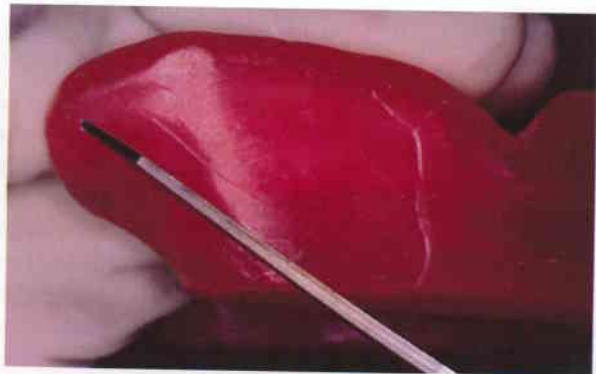## Laboratory Construction of Occlusal Rims

The occlusal rims are composed of a wax rim and a rigid base. The rims should be constructed so that the height of wax in the anterior incisor region is 10 mm, and 5 mm in the molar region. The base, composed of self-cured, light-cured or heat-cured acrylics, should also be able to be used as a base for setting denture teeth. If the upper baseplate is too thick, then interfering contacts with the ascending ramus may occur during occlusion. Any interfering contacts can be difficult to detect, but the likelihood of them occurring is reduced if the wax on the posterior aspect of the upper rim is cut away at 45° (Fig. 3.1).

## Adjusting the Upper Occlusal Rim in the Clinic

The labial face of the upper wax rim is adjusted to provide an average 90° nasolabial angle (Fig. 3.2), but further modifications may be needed during recording

Fig. 3.1. The posterior aspect of the upper rim can contact the ascending ramus of the mandible and, if undetected, can prevent an accurate jaw registration or sufficient interocclusal clearance being obtained



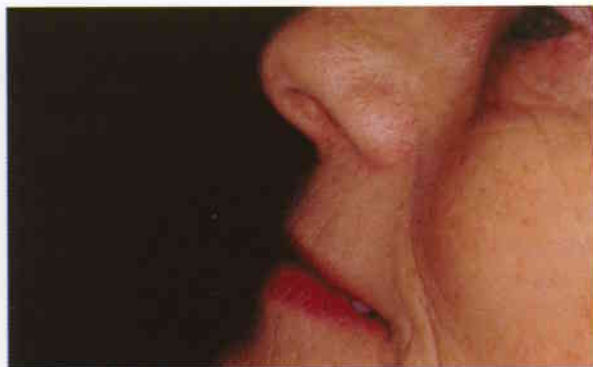

Fig. 3.2. A nasolabial angle of 90–110° is desirable, depending on the prominence of the columella

of the retruded jaw relationship to allow for marked skeletal discrepancy. The amount of wax displayed below the upper lip is often as much as 3–4 mm in the younger age groups, but only 1–2 mm in the elderly due to the loss of lip muscle tonus with age.

### Determining the Angulation of the Occlusal Plane

The correct angulation of the occlusal plane is important in obtaining balanced articulation and good aesthetics. The occlusal plane is a horizontal surface occupied by the masticatory surfaces of the upper teeth and extends from the tip of the mesioincisal edge of the upper central incisor to the tip of the mesiobuccal cusp of the upper first molar on each side. It has been assumed that the angulation of the occlusal plane in the artificial dentition must replicate that found in the natural dentition for optimum function. The teeth occupy a constant relation to other parts of the skull. Therefore, various anatomical points have been recommended to assist in determination of the correct occlusal plane orientation and position. The residual ridge, the alar-tragal line or the parotid papilla (Foley and Latta 1985) have been recommended, but all have their disadvantages.

#### *The Residual Ridge*

The occlusal plane is positioned midway between the casts, with the upper wax rim trimmed parallel to the crest of the upper and lower residual ridges. However, trimming wax occlusal records in this way may be clinically difficult.

Following loss of the natural teeth, residual ridge resorption occurs faster in the mandible than the maxilla. Using the mid-interresidual ridge distance to determine the occlusal plane results in a newly determined occlusal plane closer to the mandibular crest than that originally present in the natural dentition. Increasing the height of the upper denture relative to the lower denture has few del-



The buccal cusps of the mandibular teeth on the left side (balancing side) remain in contact with the maxillary teeth by contacting the palatal cusps. The teeth on the working side intercusate and the cusps occlude with flat surfaces on the opposing teeth (Nairn 1973). Cusps do not ride over opposing high-cusped surfaces on the working side. Little or no jaw separation is therefore observed on the working side.

Where premature occlusion exists on the working side, preventing even contact with teeth on the balancing side, then the occlusal surfaces of the working side are adjusted. It follows that the relevant buccal cusps of the upper teeth and the lingual cusps of the lower teeth should be shortened (the BULL rule). In this way there is little or no decrease in occlusal vertical dimension of the dentures.

With the semiadjustable articulators, it is possible to record the patient's individual condylar guidance using protrusive wax records. An alternative explanation for an absence of balancing side contacts in the patient's mouth may result from too-low an articulator condylar guidance setting on that side. In patients, the angle of the condylar path to the horizontal varies in the range 15–66° (Aull 1965). Therefore, if the patient's condylar path inclination is steeper than the condylar guidance, the balancing side molar teeth are separated in the patient's mouth (Jordan 1978).

Premature occlusal contacts on the balancing side can be difficult for patients to manage, as they find it difficult to obtain occlusal contact on the working side. Further protrusion of the condyle on the balancing side by the patient fails to improve the occlusion on the working side. However, by reducing the appropriate buccal cusp inclines of the lower teeth on the balancing side, the dentist can restore occlusal balance. Alternatively, premature contact on the balancing side can result from too-great a condylar guidance on the articulator and the setting of the posterior teeth with a steep lateral cusp height. If the condylar path inclination of the patient is shallow, then premature contact on the balancing side ensues (Jordan 1978).

As the lips lose muscle tone with age, many patients request increased lip support and more visible teeth. Increasing the overbite (or vertical overlap of the anterior teeth) would increase the incisal angle, which would cause a premature occlusion in protrusion. If occlusal balance is to be preserved a steeper posterior cusp height or compensating curve will be required. However, posterior teeth with high cusp angles (30° or more) tend to transmit more lateral loads to the residual ridge, which may cause instability. Therefore, it is more effective to set the upper anterior teeth further forward providing increased lip support, rather than increasing the overbite. With the upper teeth further forward, the effect on the upper lip is to lift it and make it appear shorter.

Errors in protrusive balance will be discussed in relation to setting the anterior teeth at the try-in. Adjusting the finished denture by reducing the length of the teeth can be detrimental to the aesthetics.



## Clinical Determination of the Jaw Relationship

Occlusal rims are used to determine the tooth position, occlusal vertical height and horizontal jaw relationship, and transfer this recording to the laboratory. Using this, together with the detailed written instructions provided, the technician can set the artificial teeth in the correct position. However, increasing numbers of dental surgeons are setting the anterior teeth into the wax record blocks at the chairside themselves, following completion of the jaw registration stage. With practice, this can be done quickly and has the advantage that the patient is present for discussion about their appearance while the teeth are positioned. The patient feels more involved in the denture-making process and therefore more likely to accept the new dentures.

## Laboratory Construction of Occlusal Rims

The occlusal rims are composed of a wax rim and a rigid base. The rims should be constructed so that the height of wax in the anterior incisor region is 10 mm, and 5 mm in the molar region. The base, composed of self-cured, light-cured or heat-cured acrylics, should also be able to be used as a base for setting denture teeth. If the upper baseplate is too thick, then interfering contacts with the ascending ramus may occur during occlusion. Any interfering contacts can be difficult to detect, but the likelihood of them occurring is reduced if the wax on the posterior aspect of the upper rim is cut away at 45° (Fig. 3.1).

## Adjusting the Upper Occlusal Rim in the Clinic

The labial face of the upper wax rim is adjusted to provide an average 90° nasolabial angle (Fig. 3.2), but further modifications may be needed during recording

**Fig. 3.1.** The posterior aspect of the upper rim can contact the ascending ramus of the mandible and, if undetected, can prevent an accurate jaw registration or sufficient interocclusal clearance being obtained





Fig. 3.2. A nasolabial angle of 90–110° is desirable, depending on the prominence of the columella

of the retruded jaw relationship to allow for marked skeletal discrepancy. The amount of wax displayed below the upper lip is often as much as 3–4 mm in the younger age groups, but only 1–2 mm in the elderly due to the loss of lip muscle tonus with age.

### Determining the Angulation of the Occlusal Plane

The correct angulation of the occlusal plane is important in obtaining balanced articulation and good aesthetics. The occlusal plane is a horizontal surface occupied by the masticatory surfaces of the upper teeth and extends from the tip of the mesioincisal edge of the upper central incisor to the tip of the mesiobuccal cusp of the upper first molar on each side. It has been assumed that the angulation of the occlusal plane in the artificial dentition must replicate that found in the natural dentition for optimum function. The teeth occupy a constant relation to other parts of the skull. Therefore, various anatomical points have been recommended to assist in determination of the correct occlusal plane orientation and position. The residual ridge, the alar-tragal line or the parotid papilla (Foley and Latta 1985) have been recommended, but all have their disadvantages.

#### *The Residual Ridge*

The occlusal plane is positioned midway between the casts, with the upper wax rim trimmed parallel to the crest of the upper and lower residual ridges. However, trimming wax occlusal records in this way may be clinically difficult.

Following loss of the natural teeth, residual ridge resorption occurs faster in the mandible than the maxilla. Using the mid-interresidual ridge distance to determine the occlusal plane results in a newly determined occlusal plane closer to the mandibular crest than that originally present in the natural dentition. Increasing the height of the upper denture relative to the lower denture has few del-

eterious consequences, but when the occlusal plane is placed too high, the tongue musculature must be very active to place the food on the occlusal platform. Displacement of the lower denture occurs either as a direct result of the excessive muscular activity of the tongue or indirectly by raising the lingual sulcus.

### ***Alar-Tragal Plane (or Camper's plane)***

The alar-tragal plane is used widely as a guide to positioning the occlusal plane. It allows the teeth to be set in harmony with movements of the mandibular condyle. However, the relationship between the occlusal plane of the natural teeth and the alar-tragal plane is not very close, varying often by more than 20° (D'Sonza and Bhargara 1996).

### ***The Parotid Papilla***

Standard (1957) stated that the occlusal plane should be positioned 6 mm below Stenson's duct, but no experimental data were presented. The small opening of this duct can be difficult to detect and because of this has not been generally accepted as a reliable method of detecting the occlusal plane position.

### ***Other Methods Available to Obtain the Occlusal Plane Orientation***

Classically, the occlusal plane is constructed to be parallel to interpupillary and alar-tragal lines using a Fox occlusal plane guide. However, information from other sources, e.g. old dentures, photographs or patient requests, can mean that the position of the occlusal plane has to be altered. In addition, enlarged maxillary tuberosities may prevent the occlusal plane from being made parallel to the alar-tragal line. Where possible, the occlusal plane should remain parallel to the alar-tragal plane, to relate to movement of the temporomandibular joint, but can be moved in the vertical dimension.

### ***High Lip Line, Canine Lines, and Centre Lines***

The high lip line is the upper limit of the lip during smiling and its position is carved on the anterior part of the wax rim. The distance between the high lip line and the occlusal plane should at least equal the length of the upper incisor teeth that are chosen. This avoids an unattractive display of pink acrylic above the incisor teeth when the patient smiles. Some research would indicate that a large display of teeth in women is considered attractive, but in men a more moderate display of teeth is attractive (Dunn et al. 1996; McAlister et al. 1998).

If a ruler is placed between the inner canthus of the eye and the lateral surface of the alar cartilage, it extends onto the upper rim in the region of the cusp tips of the upper canine teeth. The intercanine distance is measured with a flexible ruler, which is a useful guide to selecting the width of the upper anterior teeth. The upper canines are usually positioned at the corners of the mouth and their position can be marked on the upper wax rim at this point. The centre line is marked on the labial aspect of the upper rim using the philtrum as a guide.

## Recording the Mandibular Rest Position

The lower wax rim is trimmed to meet the upper rim at the correct occlusal vertical dimension, with the correct amount of interocclusal clearance (or freeway space). The mandibular rest position is the position passively adopted by the mandible when the associated musculature is relaxed. The patient's head must be upright during recording of the jaw relationship. Several procedures may be adopted to measure this position and hence calculate the interocclusal clearance, the space between the occlusal surfaces of the maxillary and mandibular teeth (or occlusal rims), when the mandible is in the rest position. The space is normally of the order of 2–4 mm and may need to be increased when the patient is wearing an old, worn denture which has an excessive interocclusal clearance.

Having obtained the rest position, the next stage is to adjust the wax occlusal rims so that they meet evenly at the correct occlusal vertical dimension, achieved by subtracting 2–4 mm from the rest vertical dimension. Chinagraph pencil markers are placed on the tip of the patient's nose and on their chin, and the patient asked to relax with the lips touching together lightly. This distance between the marks represents the rest vertical dimension and can be recorded using dividers or a Willis gauge. The wax rims are trimmed until they contact evenly in occlusion with the distance between the pencil marks 2–4 mm less than the rest vertical dimension. The rest vertical dimension varies according to the patient's head position, the emotional state of the patient and whether the patient is wearing a lower denture.

### *Alternative Techniques that Use the Swallowing Reflex*

Very soft wax is placed on the occlusal surface of the lower occlusal rim and the patient swallows several times. Advocates of this technique claim that it is a "physiological" determination of the vertical dimension of occlusion (Shanahan 1956). The patient swallows and the highest point of mandibular elevation is recorded as the occlusal vertical dimension (Helft et al. 1978).

Mohindra (1996) described the use of the swallowing reflex to record the occlusal vertical dimension directly by modifying the patient's existing dentures. A roll of light-curing acrylic dough (Triad, Dentsply) was placed on the occlusal

surface of the first molar region of the lower denture and placed in the patient's mouth. The patient was asked to sip water and swallow with their lips together. The lower denture was removed from the patient's mouth, and the acrylic resin cured. The occlusal surface of the lower denture was flattened and polished. The occlusal vertical dimension was later copied in constructing the definitive dentures.

Many authors consider that asking the patient to swallow prior to recording the rest vertical dimension is a satisfactory method of resetting the location of the mandible and allowing it to return to the rest position. Niswonger (1934) stated that during swallowing, the mandible moves from the rest position to the retruded contact position and then returns to the rest position. However, the likelihood that the rest position is assumed has not been demonstrated experimentally. Asking the patient, seated in the dental chair, to collect and swallow small quantities of saliva present in their mouth cannot be representative of a true swallow where quantities of fluid are usually 10–30 ml. The sensory stimuli and motor response are different in both cases. Swallowing has been shown to be an unreliable technique for recording the retruded contact position (Walker 1962).

## Recording the Horizontal Jaw Relationship

One of the most common errors in denture construction is the incorrect recording of the retruded contact position, with the result that the normal functioning of the temporomandibular joint is disturbed. When the patient closes in full retrusion, the dentures are unlikely to have occlusal balance.

The difficulty in the procedure is persuading the patient to adopt a position of full mandibular retrusion. Patients who have not worn dentures for a considerable period or have a habitual lateral or protrusive occlusion often have this difficulty. Various methods have been advocated such as asking the patient to curl back the tongue to touch the posterior border of the palatal baseplate and then close together. Another method is to ask the patient to push the mandible forward while the dentist applies gentle counter resistance to the chin. This is thought to tire the muscles tending to protrude the mandible and increases the chances of successfully recording the retruded contact position.

By marking the retruded contact position with bilateral check marks on both occlusal rims, the reproducibility of the patient's pattern of mandibular closure can be repeatedly checked. Where the check lines do not coincide, then an incorrect retruded contact position has been recorded. This necessitates further trimming of the wax to produce the correct retruded contact position.

A notch 3 mm deep is cut into the occlusal surface of the upper wax rim at about the second premolar region on each side. From the opposing area of the lower rim from the first premolar region posteriorly, 2 mm of wax is removed to allow the escape of excess wax during the subsequent registration stage. The anterior part of the lower rim preserves the occlusal vertical dimension. A 3-mm



layer of soft wax is placed on the previously reduced occlusal surface of the lower wax rim and the patient closes together in the retruded jaw relation. The wax rims must contact in the anterior region and the check marks must be coincident. The registration should be checked repeatedly, each time ensuring that the retruded position is recorded.

After the rims are disinfected, they are placed on the casts and located together. Any posterior contacts between the upper and lower casts that prevent the rims being located together are reduced.

### *Alternative Techniques that Use Graphical Methods*

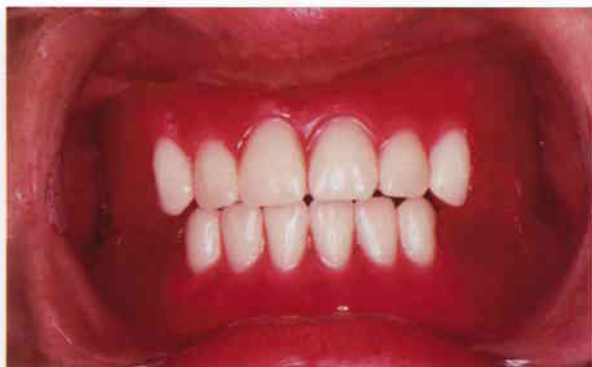These accurately record the retruded contact position using tracings of lateral mandibular movements – either extra- or intraorally. The apex of the tracing made using these techniques indicates the most retruded position of the mandible to the maxilla. The tracing must be made at the correct vertical dimension of occlusion. With intraoral records, a depression is made at the apex of the tracing which the patient uses to hold the central bearing point. Plaster is placed between the record rims to record the retruded contact position.

### **Methods of Selecting the Anterior Teeth**

The Williams classification (Williams 1914) groups the shape of natural teeth into square, tapering, ovoid or combinations of each and relates them to facial outline. According to this classification system, shape and size of anterior teeth should harmonize with facial contour. Wright (1942) measured the shape of the natural, upper central incisor in a group of over 600 young adults. He found that the majority had square-shaped teeth, but tapering facial forms. The majority of young people therefore had facial shapes that were unlike their tooth form. If choosing the mould of tooth is subjective then the patient should be involved in this process. Marunick et al. (1983) showed that, in general, members of the public prefer square teeth. They hypothesized that tapering teeth are possibly associated with tooth wear and an ageing appearance, whereas square teeth are associated with a lack of wear and youthful vigour. Young people have anterior teeth with translucent incisal edges and full interdental papillae. Attrition of the anterior teeth, gingival recession and darkening of the teeth are associated with the elderly dentition. If incisal wear occurs past the contact point, then short teeth do assume a less attractive appearance.



**Fig. 3.3.** If the anterior teeth are placed with the patient present, discussion as to the optimum tooth position is possible



### Positioning the Anterior Teeth Correctly

Following jaw registration, general dental practitioners can place the upper anterior teeth in the upper occlusal rim for an upper anterior try-in (Fig. 3.3). Guidelines for the standard arrangement of these teeth can be followed, but may need modification to allow for the harmonious positioning of these teeth in the individual patient.

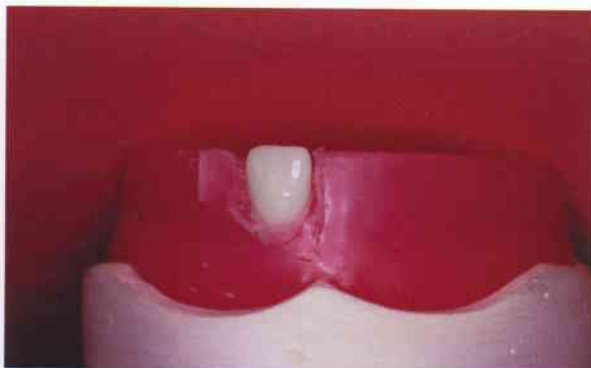#### *The Upper Central Incisor Teeth*

It has been suggested that the shape of the maxillary residual ridge in the sagittal plane provides an important guide to the position and inclination of the artificial incisor teeth. However, this is only possible where sufficient residual ridge height exists and resorption has been minimal.

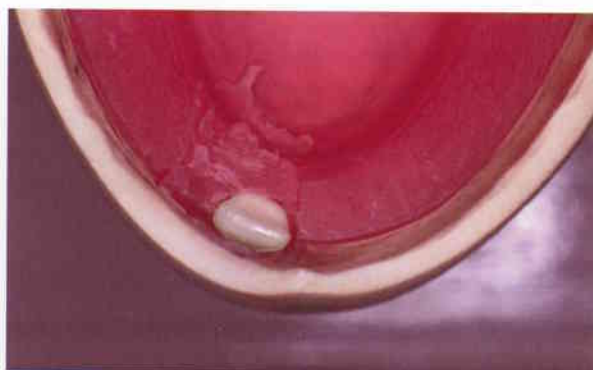A section of wax is removed from the occlusal rim lateral to the midline. The central incisor is attached to the rim with soft wax and is positioned so that the long axis diverges slightly from the midline, with the incisal edge on the occlusal plane (Fig. 3.4, p. 44). At the neck of the tooth the labial face is depressed by 2 mm into the wax rim whereas the incisal edge is in line with the rest of the wax rim (Fig. 3.5, p. 44).

#### *The Maxillary Lateral Incisor*

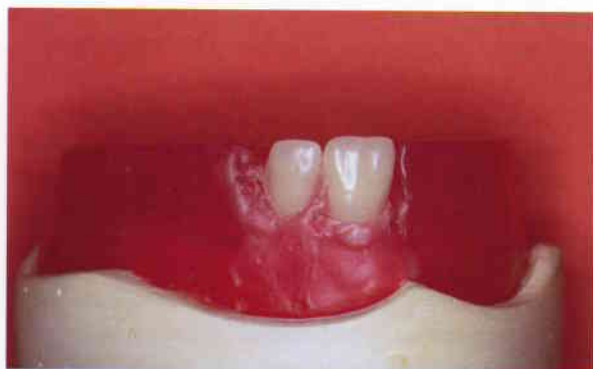The incisal edge of the upper lateral incisor is positioned parallel to the occlusal plane but 1 mm above it. The long axis of the tooth is angled more palatally and distally than the central incisor (Fig. 3.6, p. 44). The labial surface of the tooth is recessed slightly compared with the external surface of the occlusal rim.



**Fig. 3.4.** The upper central incisor is placed with the incisal edge lying on the occlusal plane and the long axis diverging slightly from the midline

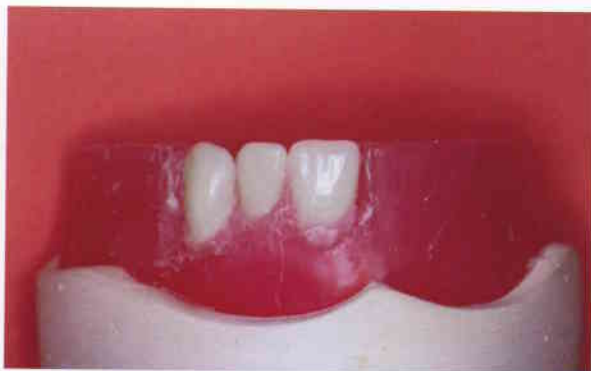

**Fig. 3.5.** The incisal edge lies in line with the rest of the wax rim

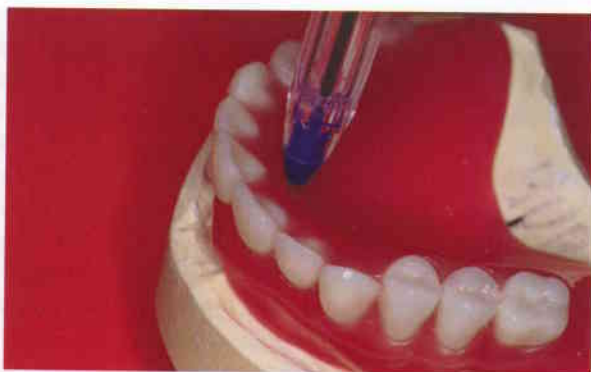

**Fig. 3.6.** The incisal edge of the maxillary lateral incisor lies about 1 mm above the occlusal plane. The long axis is inclined palatally and distally

**Fig. 3.7.** The maxillary canine is placed with the neck prominent and the long axis of the tooth perpendicular to the occlusal plane



**Fig. 3.8.** The tip of the ball-point pen indicates the position of the incisive papilla. A line joining the cusp tips of the maxillary canines should pass through the distal surface of the incisive papilla

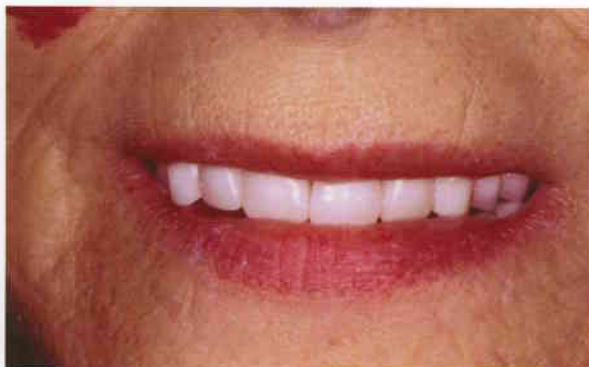

### ***The Maxillary Canines***

The maxillary canine teeth are placed at the angle of the mouth, below the ala of the nose. These teeth are arranged perpendicular to the occlusal plane, with the cusp tip touching the occlusal plane and the neck prominently placed. The canine tooth should be positioned with its labial face continuous with the labial surface of the wax occlusal rim (Fig. 3.7). A line joining the cusp tips of the canine teeth should pass through the distal surface of the incisive papilla (Fig. 3.8).

### **Arranging the Mandibular Anterior Teeth**

When viewed from the labial aspect, the mandibular central incisors are arranged over the ridge either side of the midline, perpendicular to the occlusal plane, whereas the lateral incisors and canines are mesially inclined. In Angle's class I cases, the incisal edges of the upper central incisors have a 2 mm horizontal overlap (or overjet) with the incisal edges of the lower incisors. During move-



**Fig. 3.9.** When smiling gently, the upper incisors should contact the junction between the transitional and oral epithelium. About 3 or 4 mm of the labial surface of the upper incisors is visible

ments of the articulator to simulate protrusion, incisal guidance allows the incisal edges of the mandibular and maxillary incisor teeth to touch; the posterior teeth should remain in contact. If the posterior teeth are not in contact throughout, then the lower incisor teeth need to be lowered until balanced articulation is achieved.

When viewed from the labial aspect, the lower canine teeth are mesially inclined with their cusp tips at the same level as the incisal edges of the incisor teeth. At their gingival margins, the canine teeth are prominent. In working side occlusion, the distal surface of the lower canine lightly contacts the mesiopalatal surface of the upper canine. During lateral movements, there is an absence of balancing side contacts of the anterior teeth.

The incisal edges of the upper anterior teeth should contact the junction of the oral mucosa and the transitional epithelium of the lower lip during gentle smiling (Fig. 3.9) and when the patient pronounces the letters "f" or "v". The patient's opinion is sought about the upper anterior tooth arrangement and if this is approved, the remainder of the teeth can be placed by the laboratory technician. Where the dental practitioner wishes to set both the upper and lower anterior teeth and gain the patient's approval for the appearance of the anterior teeth, the incisal guidance becomes fixed. When setting the posterior teeth in occlusal balance, the technician will only be able to manipulate the cusp height and compensating curves and not the incisal guidance.

### Positioning the Posterior Teeth

The technician usually positions the upper posterior teeth and then the lower teeth. In general, positioning the palatal cusps of the maxillary posterior teeth over the crest of the lower residual ridge allows maximum stability of the lower denture (Bissasu 1992). Lingual placement of the lower posterior teeth invariably causes displacement of the denture during tongue movement and should therefore be avoided.

### ***The Maxillary Premolar Teeth***

Both cusps of the upper premolar teeth should lie on the occlusal plane, positioned over the crest of the lower ridge. If a ruler is placed against the buccal surface of the two premolars on each side, then a line drawn between the buccal and palatal cusps of each tooth should be at right angles to the ruler.

### ***The Maxillary Molar Teeth***

The maxillary first molar is placed with the mesiopalatal cusp on the occlusal plane, while the mesiobuccal cusp is raised 0.5 mm and the distal cusps 1 mm above the occlusal plane. The mesiobuccal surface of the first molar continues the same buccal contour as the premolar teeth, but the distobuccal surfaces are angled slightly palatally to follow the shape of the maxillary ridge.

The maxillary second molar is positioned with its buccal surface in line with that of the maxillary first molar. The second molar is arranged above the occlusal plane with the occlusal surface facing in a distal and slightly buccal direction. The slight anteroposterior and lateral inclinations of the molar teeth provide the compensating curves.

### ***The Mandibular Posterior Teeth***

The mandibular first molar is positioned over the crest of the lower ridge with its central fossa occluding with the mesiopalatal cusp of the maxillary first molar. Providing balanced articulation while setting the teeth is essential. Therefore on the working side there should be occlusal contact between the mesiobuccal cusp of the mandibular first molar and the marginal ridges of the upper second premolar and the first molar.

The mandibular second premolar should occlude with the area formed by the marginal ridges of the maxillary first and second premolars. The mandibular second molar is positioned with its central fossa occluding with the mesiopalatal cusp of the maxillary second molar and its mesiobuccal cusp contacting the marginal ridge between the first and second maxillary molar teeth. The mandibular first premolar is arranged to contact the distal surface of the maxillary canine tooth and the marginal ridge of the maxillary premolar. Working side and balancing side contacts are established.



## Anatomical Guides to Positioning the Posterior Teeth

### *Biometric Guidelines*

A raised fibrous ridge on the palatal surface of the upper residual ridge distinguishes the palatal mucosa from the vestibular mucosa and can be used as a guide to positioning the maxillary teeth. Watt (1960) used tattoo spots placed near the palatal gingivae, and found that following extraction of the teeth they could be subsequently identified as the palatal gingival vestige. However, the "palatal gingival vestige" is present in patients with severe hypodontia where the palatal gingivae cannot contribute to the vestige. In addition, a structure resembling the palatal gingival vestige can be identified on the palatal mucosa of neonates prior to eruption of any teeth.

The distance between the palatal gingivae and the labial or buccal surface of the teeth is termed the "buccopalatal breadth". This is, on average, about 6 mm in the incisor region, 8 mm for the canines, 10 mm for the premolars and 12 mm for the molars. Therefore, by distinguishing the palatal gingival vestige, the position of the buccal surface of the artificial teeth can be readily identified (Fig. 3.10). These measurements are based on European studies of Caucasian populations (Watt et al. 1967); data for other racial groups are not available.

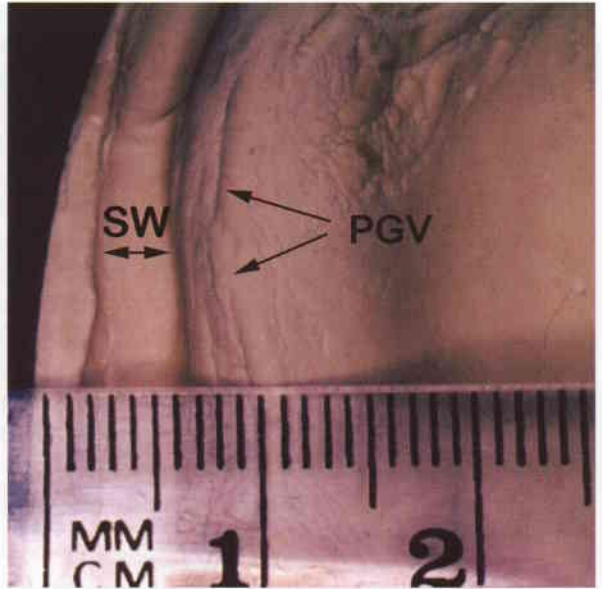
### *Width of the Maxillary Arch*

This technique uses the interpremolar and intermolar distances as multiples of the intercanine distance. So, for example, the distance between the maxillary, first molar buccal cusps is 1.5 times the distance between the maxillary canine teeth. This method does not accurately locate the maxillary teeth, but encourages an appreciation of the need to provide sufficient tongue space in a wide maxillary arch. Despite severe resorption of the residual ridge, the periphery, teeth and buccal surface of the denture contacts the mucosa of the lips and cheeks to form a valve-like seal (Fig. 3.11). Sudden displacement of the denture away from the ridge will cause the mucosa to be sucked against the denture to resist its movement.

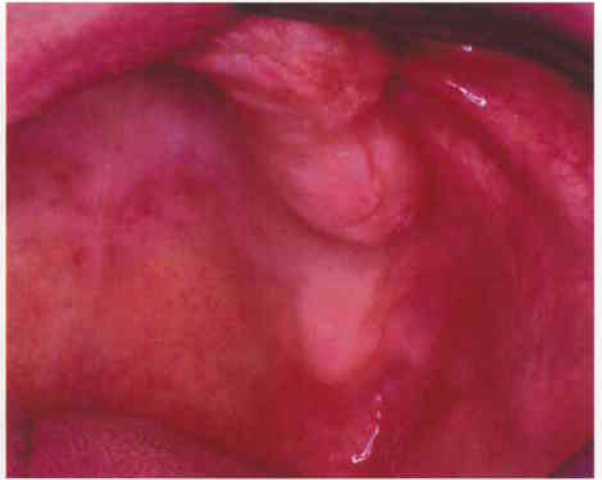To keep occlusal forces on the denture vertical in the mandibular body and prevent denture displacement during function, the lower posterior teeth should not reach the anterior aspect of the ascending ramus of the mandible. If the teeth are placed over the ascending ramus, the occlusal forces will not be vertical and will force the denture anteriorly during function. To prevent this occurrence, only two premolar teeth and one molar tooth may need to be routinely placed on the denture base. Reducing the occlusal table has the additional benefit of reducing the pressure applied to the underlying ridge.



**Fig. 3.10.** The palatal gingival vestige (PGV) is a raised fibrous band (arrow) over the maxillary ridge and is used as a guide to placement of the buccal surface of the teeth. Thus, during the impression stage, the correct width of the sulcus must be obtained (SW sulcus width). The buccal surface of the teeth and flange then form a peripheral seal with the lips and cheeks



**Fig. 3.11.** Despite severe resorption of the residual ridge, application of “biometric guidelines” will allow the periphery and buccal surfaces of the denture to contact the mucosa of the lips and cheeks. Sudden displacement of the denture away from the ridge will cause the mucosal tissues to be sucked against the denture and hence resist this movement



### *The Inter-Ridge Space*

The inter-ridge space, in the vertical plane, also governs the height of the posterior teeth. Where there is little inter-ridge space available, acrylic posterior teeth are more retentive than porcelain teeth as they chemically bond to the acrylic baseplate.

## Alternative Occlusal Arrangements of Posterior Tooth

There are many advocates of different occlusal schemes, but little scientific data available to aid in choosing between them. Some questionnaires to patients provided with complete dentures incorporating anatomic, semianatomic or nonanatomic teeth have not revealed any significant differences in patient satisfaction (Lamoureux et al. 1999).

Ardran et al. (1957) suggest that as dentures may move away from the mucosal tissues during function sometimes by more than several millimetres, balanced occlusion may not be necessary. However, such denture movement should necessitate balanced articulation during mastication allowing the dentures to be resealed, and therefore preventing local traumatic mucosal overloading. Balanced occlusion is essential, therefore, but the extreme border movements may only be used rarely in the nonbruxing patient (Jones 1972).

### *Occlusal Pivot Appliances*

These are primarily modifications to the patient's existing dentures, and are used where the lower denture has become unsuccessful perhaps due to an increased interocclusal clearance or excessive wear (Fig. 3.12). Light or self-curing acrylic is placed on the occlusal surface of the lower denture to occlude with the upper second premolar and first molar teeth. If the upper teeth are coated with petroleum jelly, the acrylic does not stick to the upper denture. The acrylic dough is polymerized and polished. Often, several adjustments are required to the dentures before they can be successfully worn. There is a risk that patients may be unable to adapt to the modified prostheses so that their dentures cannot be worn. They are useful in allowing patients to learn to adapt to a new vertical height and jaw relationship prior to the construction of new dentures.

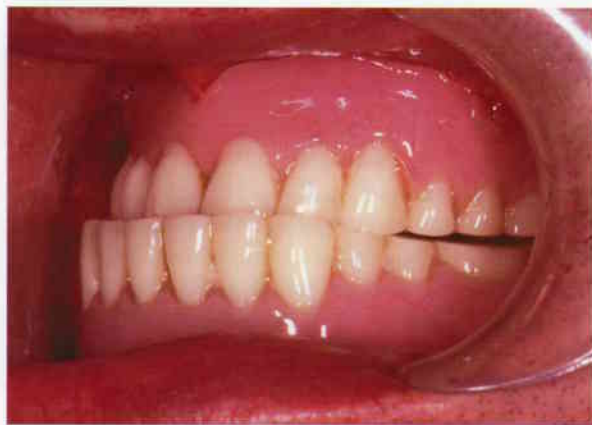

Fig. 3.12. By restoring the occlusal vertical dimension on the patient's old dentures, the dentist will improve the chances of obtaining a satisfactory jaw registration when constructing new dentures

An alternative strategy involves constructing new copy dentures with reduced interocclusal clearance and flat bilateral posterior contacts. Murrell (1974) recommended using acrylic resin blocks for posterior teeth to provide a "non-interfering posterior occlusion".

### ***Nonanatomical Teeth Set on a Flat Occlusal Plane***

In this technique, the occlusal surfaces of the molars and premolars and the incisal edges of the central incisors and canines are set on a flat plane parallel to the upper and lower ridge crests (Brudvik and Wormley 1968). There is no intercuspation of the molar teeth, and no balanced articulation, and masticatory efficiency is usually poor. Aesthetics are poor as the flat plane occlusion does not allow an overbite. An anterior overbite may be possible if the second molar teeth are inclined so that they contact in protrusion, forming a three-point contact with the anterior teeth (Nimmo and Kratochvil 1985). However, balancing contacts in lateral excursions are usually absent. This technique may have application in those patients who chew with vertical mandibular movements only.

Shetty (1984) constructed two sets of dentures for each of 40 patients. The first set of dentures was designed with a flat occlusal plane and nonanatomic teeth. The second set used anatomic teeth set in occlusal balance. Most patients preferred the cusped anatomic teeth as all types of food could be chewed. When the patients were asked about the nonanatomic teeth, the vast majority stated that they could only chew soft food and found them relatively unsatisfactory.

### ***Plaster-Pumice Occlusal Rims***

This technique allows the patient to form their own occlusal plane and degree of curvature of the compensating curves, using grinding masticatory movements. The jaw registration is recorded using conventional wax record rims and the secondary casts articulated. A new rim is constructed using plaster and pumice (in equal proportions), attached to a baseplate using wire loops (Figs. 3.13 and 3.14). The height of each plaster-pumice rim is about 2 mm greater than that previously recorded during the wax registration (Figs. 3.15 and 3.16). The plaster-pumice rims are placed in the patient's mouth and the patient asked to grind them together slowly. When the patient has ground the rims to the same height as recorded previously during the jaw registration stage with the wax occlusal rims, they can be removed. After disinfecting the plaster-pumice rims, they are replaced on the articulator, and nonanatomical teeth set to the functionally determined occlusal plane.

Patients may find the accumulation of plaster and pumice debris in their mouth irritating and unpleasant, but occasional rinsing can overcome this difficulty. In those with resorbed residual ridges, movement of the plaster-pumice

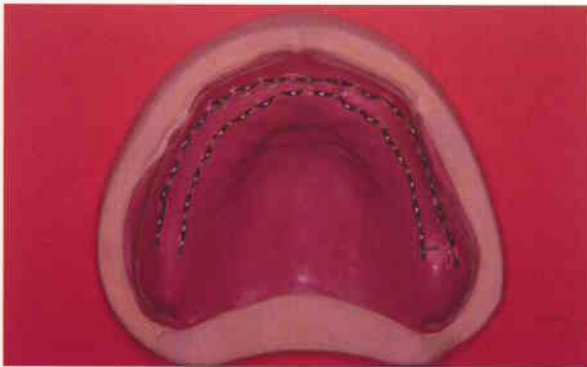


Fig. 3.13. The plaster-pumice rims are constructed using an upper thermoplastic shellac baseplate with attached wire loops. The wire loops are necessary to hold the plaster and pumice rim

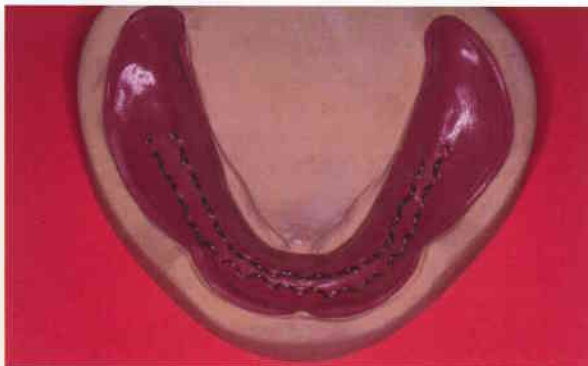

Fig. 3.14. As with the upper rim, the lower rim is constructed with a shellac baseplate and wire loops

rims over the ridge during the grinding movements can cause pain and result in an inaccurate recording.

### ***Metal Template Guides***

Metal templates can be used to provide an approximation to occlusal balance using cusplless teeth. The shape of the template assists in arranging the teeth with lateral and anteroposterior compensating curves (Fig. 3.17), but the negative incisal guidance that is necessary can compromise denture appearance. The teeth are usually set with the occlusal plane angled parallel to the maxillary and mandibular residual ridges for maximum stability.

### ***Lingualized Occlusion***

Lingualized occlusion uses anatomically shaped upper teeth with prominent palatal cusps which occlude with wide, deep fossae on the lower posterior teeth

Fig. 3.15. The plaster-pum-ice rim is constructed for the upper. The occlusal height is 2 mm greater than the previously recorded height for the upper wax rim registration

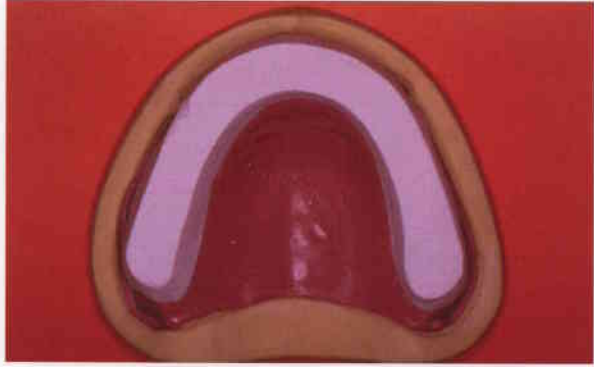

Fig. 3.16. The plaster-pum-ice rim is constructed for the lower

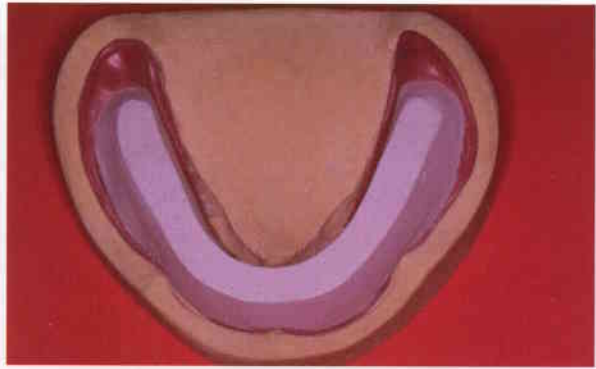
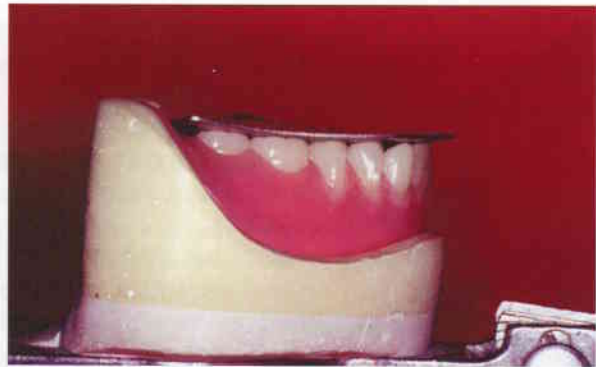
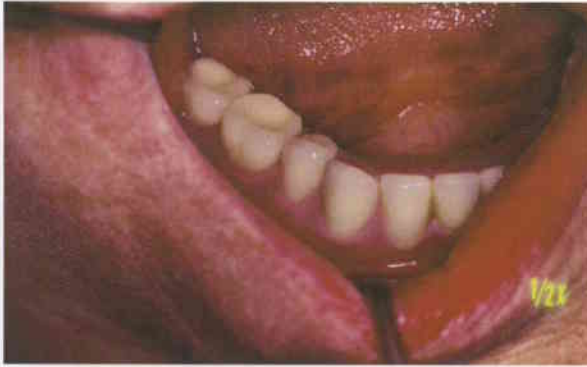
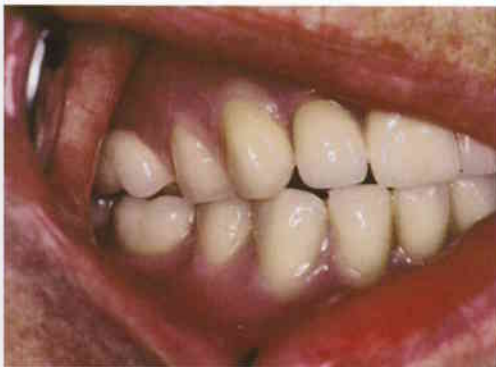Fig. 3.17. Metal template guides are used with non-anatomical teeth. They can assist with obtaining an approximation to occlusal balance







**Fig. 3.18.** Lingualized occlusion is characterized by the cup-shaped occlusal surface of the lower molar teeth



**Fig. 3.19.** In centric occlusion the buccal cusps of the molar teeth are not in contact. The palatal contact of the molar teeth combines with the buccal cusp contact of the first premolar tooth to produce a scissor-like action

(Fig. 3.18). Each tooth has a single occlusal contact and mastication resembles the grinding action of a pestle and mortar. In the intercuspal position, the buccal cusps of the second premolar and molar teeth do not contact, whereas the buccal cusps of the lower first premolar tooth occlude with the mesial fossa of the upper first premolar. The buccal cusps of the upper teeth and the lower first premolar teeth retain a natural tooth shape, providing a satisfactory appearance. The buccal cusp contact of the lower first premolar tooth and the palatal cusp contact of the molar teeth may add a scissor-like action to the masticatory stroke (Fig. 3.19). Masticatory function with these teeth is therefore usually satisfactory.

Clough et al. (1983) constructed two sets of dentures for each of 30 edentulous patients. One denture pair was constructed using lingualized occlusion, whereas the other pair was produced using nonanatomic teeth. Two thirds of their patients preferred the dentures with the lingualized occlusion, because of improved function and aesthetics. Patients wanted preservation of the upper buccal cusps for a better appearance. Only 25% of the patients, who had previously used complete dentures with a worn occlusal surface, preferred the nonanatomic dentures. Ohguri et al. (1999) found that with lingualized occlusion, a large occlusal force



is not needed for mastication, and consequently the stress to the supporting tissues is reduced.

Despite support in the literature for providing lingualized occlusion, the technique is taught in a minority of American and European dental schools. Arbree et al. (1996) found that lingualized occlusion is taught in only 11% of North American dental schools.

## The Morphology of the Denture Space

In deciding whether the natural teeth are in a stable position following orthodontic retraction, the "neutral zone" concept has been applied. This is commonly regarded as a zone where the forces generated by the cheeks and lips are in equilibrium with those of the tongue. For the orthodontically retracted upper incisors to remain in position rather than relapse, the tongue forces thrusting the incisors forward during swallowing or speaking must be balanced by the labial forces tending to push lingually. However, studies that have measured the lingual, labial and buccal forces on the natural teeth have shown that these forces are not equal during function. Kydd (1957) used a manometer to measure the maximum pressure on the lingual aspect of the teeth during swallowing and found that it does not equal the labial pressure exerted. Winders (1958) used strain gauges attached to the incisor and molar regions of upper and lower jaws, and again found that the maximum lingual force is greater than that of the lips and cheeks. The form of the dental arch may be predominantly genetically determined, with muscular forces highly adapted to the arch shape. It would seem desirable to ensure that dentures function in harmony with the changeable, oral muscle activity.

In a classic study, Heath (1970) asked edentulous individuals to mould a soft gel with their tongue and cheeks while at rest and during swallowing. In some sites, the shapes of gel moulded at rest were different from those moulded during swallowing. In these sites, the denture with a shape similar to the functional gel impressions recorded at rest would not remain stable during swallowing. However, simultaneous muscle activity at other more distant sites might resist displacement of the denture. For example, the buccal musculature, rather than the labial musculature, might resist the forward thrust of the tongue during swallowing. The term "denture space" is more appropriate than "neutral zone" as it considers the functional environment of the denture as a whole.

Fish (1933) considered that the ideal shape for the polished surface of the denture would include buccal concavities into which the buccinator muscle would fall. The buccinator muscle arises from the pterygomandibular raphe, mandible and maxilla and converges on the modiolus. Some fibres pass into the upper and lower lips. Contraction of the buccinator muscle therefore has the effect of flattening the cheeks, and pulling the closed lips back against the teeth. The buccinator, essentially an accessory muscle of mastication, gently contacts the buccal surface of the denture during mastication as it transfers food from the cheek

pouch to the area between the teeth. This muscle action will not press unretentive dentures back onto the residual ridges, but may prevent further dislodgement. Careful contouring of the buccal surface of the denture can prevent accumulation of food in the buccal sulcus.

Functional determination of the shape of the denture flange often produces a convex shape to the buccal flange (Beresin and Schiesser 1976), not a concave surface as recommended by Fish (1933). This shape of the buccal denture surface increases the peripheral seal with the denture, allows the cheeks to assist in denture retention and reduces the ingress of food debris (Tyson and McCord 2000). Neil and Glaysher (1982) constructed complete dentures for four subjects, using different methods of posterior tooth placement. Whilst wearing the dentures with concave buccal polished surfaces, the lingual force measured against the molar teeth was greater than the buccal pressure when the patient said the letter "m". There is little experimental evidence to support overtly concave buccal flanges.

Particularly in the molar region, where there has been much residual ridge resorption, a concave buccal flange shape to the denture is contraindicated.

## Clinical Physiology Studies

Electromyography (the recording of a muscle's electrical activity) has been used to study the activity of different muscle groups during function with various denture designs. However, it is rarely possible to isolate the activity of any particular facial muscle because of the proximity of different muscles in the face. In addition, many facial muscles lack thick fascia segregating them from their neighbours.

## Impression Techniques to Record the Muscular Environment

Many guides concentrate on the correct positioning of the upper denture teeth, but patients complain mostly of lower denture instability. The labial and lingual musculature are used to determine the optimal tooth position for stability by patients performing tasks such as sipping water and speaking while a soft impression material sets in their mouth. The resulting functional impression (or piezogram) represents the unconstrained action of the lips and cheeks. The artificial teeth and polished surface are placed within the space recorded by the piezogram.

Elastomeric impression materials are convenient and easy to use and can be utilized to outline the denture space. When the jaw registration has been completed, an upper try-in is requested which occludes posteriorly on the articulator with a vertical acrylic flange originating from the lower acrylic baseplate. Wire loops are attached to the baseplate in the anterior region over the crest of the re-

sidual ridge to retain the silicone impression material. The patient forms the denture space by moulding the silicone material with functional movements.

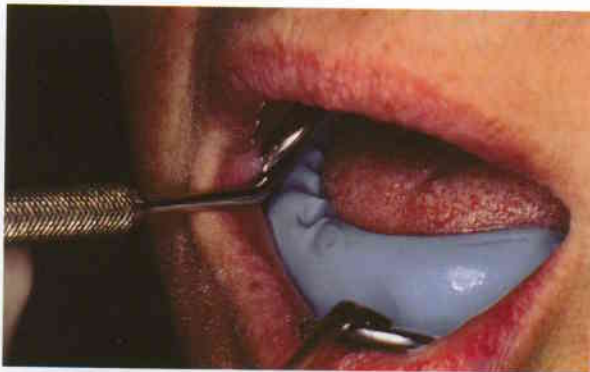### *Clinical Methodology for Recording the Denture Space*

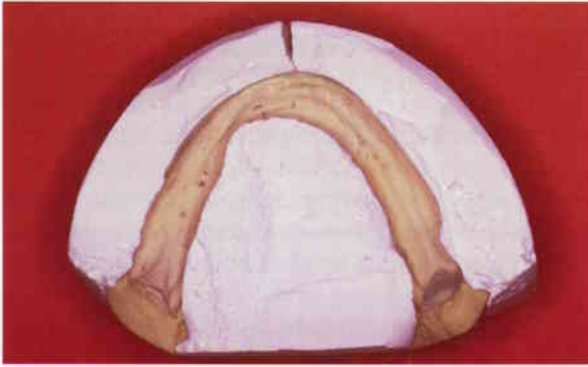The jaw registration is recorded as usual and the secondary casts articulated. The upper trial denture is constructed and the upper teeth placed according to biometric principles (i.e. in the position occupied by the natural teeth). A lower, close-fitting light-cured acrylic tray is constructed on the secondary cast, with a vertical extension that occludes in the premolar region with the upper premolar teeth. There is much disagreement as to the optimal material for the patient to mould. With use of a low viscosity material, such as Coe-Comfort (Coe Laboratories, Chicago, Ill., USA), there is a danger that the material is too fluid and the piezogram will not form a sufficient height of material. Also, during subsequent handling the recording is easily distorted. Silicone putty has sufficient viscosity to be a satisfactory material. When mixed, the putty is attached to the lower tray which is placed in the patient's mouth. The patient is asked to count slowly or read out-loud a short passage. The vertical acrylic fin acts as an occlusal stop, preserving the previously recorded occlusal vertical dimension. Buccal or lingual indices can be cast against the piezogram or alternatively, an alginate mould constructed round the piezogram as in the copy denture technique.

The patient makes functional movements such as gentle sucking and blowing (Fig. 3.20). Once the elastomeric impression material has been moulded in the patient's mouth, a plaster matrix is cast against the impression (Fig. 3.21). When the impression material is removed, the space between the plaster walls represents the denture space. The lower teeth of the try-in must be set inside the denture space.

Improved denture stability results when artificial teeth are in the correct position. Correct lingual contouring of the denture avoids the lower molar teeth overhanging the tongue, and so improves denture stability.

Fig. 3.20. Silicone material after moulding in the patient's mouth represents the denture space





**Fig. 3.21.** Once the impression (e.g. alginate or elastomeric material) has been moulded in the patient's mouth, a plaster matrix is cast against the impression. When the impression has been removed, the space between the plaster represents the denture space

### **Research Studies**

Barrenas and Odman (1989) constructed two sets of dentures for patients of conventional and piezogram design. Over two-thirds of the patients preferred the piezogram design, despite being unaware of the purpose of the study. Patients in this study preferred the improved retention, the reduced amount of food trapping and the better appearance associated with the piezogram.

### **Modifying the Buccal Surface of the Denture**

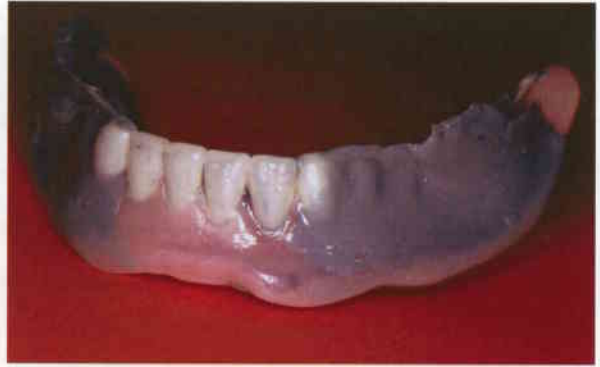Muscular movements of the tongue, lips and cheeks can be used to modify the shape of the buccal polished surface of the trial denture prior to processing. A light-bodied silicone impression material is applied to the buccal surface of the trial denture. With both dentures in place, the patient is asked to perform grimacing and speaking movements to record the polished surface shape. No adhesive for the impression material is necessary. Buccal placement of the teeth causes the impression material to be wiped away by tissue movement. The silicone impression material provides a guide to the correct shape of the buccal surface of the trial denture and accurate molar tooth placement (Fig. 3.22).

Merkeley (1954) recommended flowing impression material over the wax trial periphery to better define its buccal contour. However, the shape of the buccal surface that results is highly dependent on the viscosity of the impression material used. Alginate is too viscous and distension of the cheeks may arise.

### **Other Muscle Activity in Denture Retention**

It is thought that muscular control of dentures is an extremely important factor in denture retention. During incision into food, the posterior palatal edge of the upper complete denture often moves away from the palatal tissues as the denture

**Fig. 3.22.** Use of narrow posterior teeth prevents conflict with the surrounding muscular environment. Applying a light-bodied silicone material to the buccal surface of the trial denture can provide a guide to the correct posterior tooth position and polished surface shape



pivots around the upper labial ridge. With the practiced denture wearer, the posterior surface of the tongue automatically rises to replace the denture into position. The lower denture is also retained by coordinated muscle activity of the tongue and cheeks.

One of the commonest causes of loose dentures is the overextended denture flange where the buccinator muscle pushes the denture off the ridge even when the patient's mouth is at rest. This occurs particularly over the retromolar pad as the buccinator swings laterally from the pterygomandibular raphe to its mandibular origin. This denture displacement often arises because of faults in the impression-taking procedure, e.g. overextended trays, insufficient border moulding of the periphery or the use of viscous impression materials which distend the sulcus. Dentures must be designed to work in harmony with the surrounding oral musculature.

## References

- Ardran GM, Kemp FH, Munz FR (1957) Observations on the behaviour of full dentures. An X-ray cinematographic study with special reference to the Perspex tray impression method. *Dent Pract Dent Record* 7:180-186
- Arbree NS, Fleck S, Askinas SW (1996) The results of a brief survey of complete denture prosthodontic techniques in predoctoral programs in North American dental schools. *J Prosthodont* 5:219-225
- Aull AE (1965) Condylar determinants of occlusal patterns. *J Prosthet Dent* 15:826-846
- Barrenas L, Odman P (1989) Myodynamic and conventional construction of complete dentures: a comparative study of comfort and function. *J Oral Rehab* 16:457-465
- Beresin VE, Schiesser FJ (1976) The neutral zone in complete dentures. *J Prosthet Dent* 36:356-367
- Bissasu M (1992) A guide for the buccolingual position of the posterior teeth. *J Prosthet Dent* 67:731-732
- Brudvik JS, Howell PG (1990) Evaluation of eccentric occlusal contacts in complete dentures. *Int J Prosthodont* 3:146-157
- Brudvik JS, Wormley JH (1968) A method of developing monoplane occlusion. *J Prosthet Dent* 19:573-580



- Clough HE, Knodle JM, Leeper SH, Pudwill ML, Taylor DT (1983) A comparison of lingualized occlusion and monoplane occlusion in complete dentures. *J Prosthet Dent* 50:176-179
- D'Sonza NL, Bhargara K (1996) A cephalometric study comparing the occlusal plane in dentulous and edentulous subjects in relation to the maxillomandibular space. *J Prosthet Dent* 75:177-182
- Dunn WJ, Murchison DF, Broome JC (1996) Esthetics: patients' perceptions of dental attractiveness. *J Prosthodont* 5:166-171
- Fish WE (1933) Using the muscles to stabilize the full lower denture. *J Am Dent Assoc* 20:2163-2169
- Foley PF, Latta GH Jr (1985) A study of the position of the parotid papilla relative to the occlusal plane. *J Prosthet Dent* 53:124-126
- Heath R (1970) A study of the morphology of the denture space. *Dent Pract Dent Record* 21:109-117
- Helft M, Cardash H, Kaufman C (1978) Combining final impressions with maxillo-mandibular relation records in stabilized record bases. *J Prosthet Dent* 39:135-138
- Jones PM (1972) The monoplane occlusion for complete dentures. *J Am Dent Assoc* 85:94-100
- Jordan LG (1978) Arrangement of anatomic-type artificial teeth into balanced occlusion. *J Prosthet Dent* 39:484-494
- Kydd WL (1957) Maximum force exerted on the dentition by perioral and lingual musculature. *J Am Dent Assoc* 55:646-651
- Lamoureux J, Taché R, de Grandmont P (1999) Patient evaluation of treatment success as related to denture tooth type. *Int J Prosthodont* 12:272-278
- Marunick MT, Chamberlain BB, Robinson CA (1983) Denture aesthetics. An evaluation of laymen's preferences. *J Oral Rehab* 10:399-401
- McAlister RW, Harkness EM, Nicol JJ (1998) An ultrasound investigation of the lip levator musculature. *Eur J Orthodont* 20:713-720
- Merkeley HJ (1954) Labial and buccal accessory muscles of mastication. *J Prosthet Dent* 4:327-334
- Mohindra NK (1996) A preliminary report on the determination of the vertical dimension of occlusion using the principle of the mandibular position in swallowing. *Br Dent J* 180:344-348
- Murrell GA (1974) The management of difficult lower dentures. *J Prosthet Dent* 32:243-250
- Nairn RI (1973) Lateral and protrusive occlusions. *J Dent* 1:181-187
- Nairn RI, Shapiro MMJ (1995) *Prosthetic dentistry glossary (revised)*. Produced by a working party from British Society for the Study of Prosthetic Dentistry (BSSPD) and approved by the Council of BSSPD. Quintessence Publishing, London
- Neil DJ (1967) Studies of tooth contact in complete dentures. *Br Dent J* 123:369-387
- Neil DJ, Glaysher JK (1982) Identifying the denture space. *J Oral Rehab* 9:259-277
- Nimmo A, Kratochvil FJ (1985) Balancing ramps in nonanatomic complete denture occlusion. *J Prosthet Dent* 53:431-433
- Niswonger ME (1934) The rest position of the mandible and the centric relation. *J Am Dent Assoc* 21:1572-1582
- Ohguri T, Kawano F, Ichikawa T, Matsumoto N (1999) Influence of occlusal scheme on the pressure distribution under a complete denture. *Int J Prosthodont* 12:353-358
- Shanahan TEJ (1956) Physiologic vertical dimension and centric relation. *J Prosthet Dent* 6:741-747
- Shetty NS (1984) Comparative observations of the use of cusp and zero-degree posterior teeth. *J Prosthet Dent* 51:459-60
- Standard SG (1957) Establishing the plane of occlusion in complete denture construction. *J Am Dent Assoc* 54:845-847



- Tyson KW, McCord JF (2000) Chairside options for the treatment of complete denture problems associated with the atrophic (flat) mandibular ridge. *Br Dent J* 188:10-14
- Walker RC (1962) A comparison of jaw relation recording methods. *J Prosthet Dent* 12:685-694
- Watt DM (1960) Morphological changes in the denture bearing area following extraction of maxillary teeth. PhD thesis. University of Edinburgh
- Watt DM, Durran CM, Adenubi JO (1967) Biometric guides to the design of complete maxillary dentures. *Dent Mag Oral Top* 84:109-113
- Williams JL (1914) The temperamental selection of artificial teeth, a fallacy. *Dent Digest* 20:243-259
- Winders RV (1958) Recent findings in myometric research. *Angle Orthodont* 28:226-235
- Wright WH (1942) Correlation between face forms and tooth forms in young adults. *J Am Dent Assoc* 29:1388-1392

---

## 4 The Trial Denture

|                                                                 |    |
|-----------------------------------------------------------------|----|
| Retention and Stability in the Patient's Mouth ..               | 64 |
| Anterior Tooth Position .....                                   | 65 |
| Horizontal and Vertical Jaw Relationship .....                  | 68 |
| Developing Balanced Articulation<br>with Anatomical Teeth ..... | 69 |
| Articulation with Cuspless Posterior Teeth ..                   | 70 |
| Articulation in Lingualized Occlusion .....                     | 70 |
| Simple Hinge Articulators .....                                 | 70 |
| Average Value Articulators .....                                | 71 |
| The Facebow .....                                               | 72 |
| Adjustable Articulators .....                                   | 72 |
| The Closest Speaking Distance .....                             | 72 |
| Colouring the Labial Flange .....                               | 73 |
| Postdam .....                                                   | 73 |
| Undercuts .....                                                 | 74 |
| Providing Tin-Foil Relief .....                                 | 74 |
| Liaison with the Laboratory .....                               | 74 |
| The Complete Upper Denture .....                                | 75 |
| The Complete Lower Denture .....                                | 76 |
| References .....                                                | 77 |

Several features of the trial denture should be checked prior to processing the denture in heat-cured acrylic resin. The dentist should ascertain that the prescription given to the technician has been followed and that the quality of the waxing up and the arrangement of the teeth on the cast are satisfactory. The centre line and position of the upper anterior teeth should correspond with that prescribed by the wax occlusal rims. In the vertical dimension, the separation of the casts on the articulator with the trial dentures should be the same as with the wax record rims.

### Retention and Stability in the Patient's Mouth

Retention of the trial dentures is assessed by applying a vertical force towards the occlusal plane. Overextension of the wax flanges can often cause poor retention, especially in the area of frenal attachments. By making functional movements with one hand while stabilizing the try-in with the other, the areas of peripheral overextension can be detected. The width and length of the wax periphery can then be reduced so that movement of the try-in is avoided. The mentalis muscle may cause displacement of the trial denture as the muscle insertion is often close to the crest of the residual ridge, and judicious adjustment of the wax periphery may be necessary. The lingual extension of the lower trial denture can be assessed by asking the patient to perform tongue movements while applying a gentle occlusal force with the fingers. The patient should curl the tongue back, place the tongue into the cheeks in turn and also protrude the tongue to contact the upper lip. Any lifting of the try-in, indicating overextension, is detected visually and felt with the dentist's fingers. If the tongue contacts the denture teeth during these tongue movements, the try-in may be displaced giving a false impression of overextension. Adequate frenal relief is essential, but must be conservative to prevent loss of peripheral seal.

Stability is the resistance of the denture to displacing forces applied to the occlusal surface of the denture. This is difficult to assess in some patients in whom the tongue retracts on opening the mouth fully, and forms a muscular wall protecting the pharynx. In this position, the tongue offers little positive support to the trial denture. The position of the tongue can be assessed with the mouth half-open; the lateral margin of the tongue should lie over the lingual cusps of the lower molar teeth. When the height of the lower teeth is too great, the tongue will not participate in denture retention. The level of the occlusal plane may be altered by drawing the desired position on the buccal surface of the lower teeth using a wax pencil. The technician is asked to alter the occlusal height of the lower teeth to this new level.

## Anterior Tooth Position

The incisal edges of the anterior teeth should lie on a line parallel to the interpupillary line. The occlusal plane of the teeth should be parallel to the alar-tragal line. The Fox occlusal plane guide may be used to confirm this.

The patient is given a hand mirror and asked to comment freely on the appearance of the trial denture. In particular, they are asked to comment on the colour, size and position of the teeth (Fig. 4.1). Minor adjustments to the anterior teeth can be carried out at the chairside. The incisal edge of the upper incisors and the tip of the upper canine teeth lie on the occlusal plane. The upper lateral incisal edges lie 1 mm above the occlusal plane. The centre lines of upper and lower teeth should be coincident with the midline of the patient's face.

However, patients' opinions of their desired appearance will often differ quite markedly from that of their dentist. Many patients prefer a symmetrical appearance to their anterior dentition (Brisman 1980), whereas the dentist will often favour individualistic arrangements of the anterior teeth. The facial features are highly symmetrical about the midline (Brodbelt et al. 1984), and if the arrange-

Fig. 4.1. The patient is asked to comment on the anterior tooth position, colour, shape and size

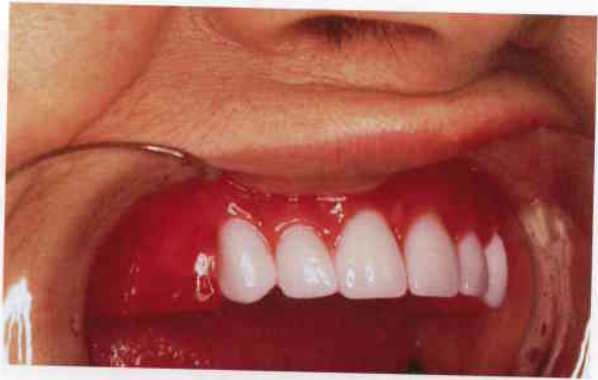
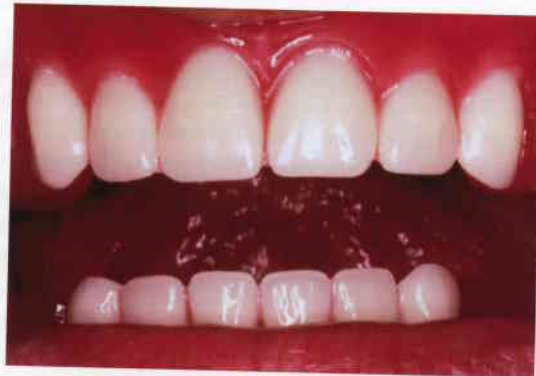
Fig. 4.2. The position of the anterior teeth should conform to that prescribed by the wax occlusal rim. The horizontal jaw relationship should be the same in the patient's mouth as on the articulator. This should be checked by scribing vertical lines on the two rims



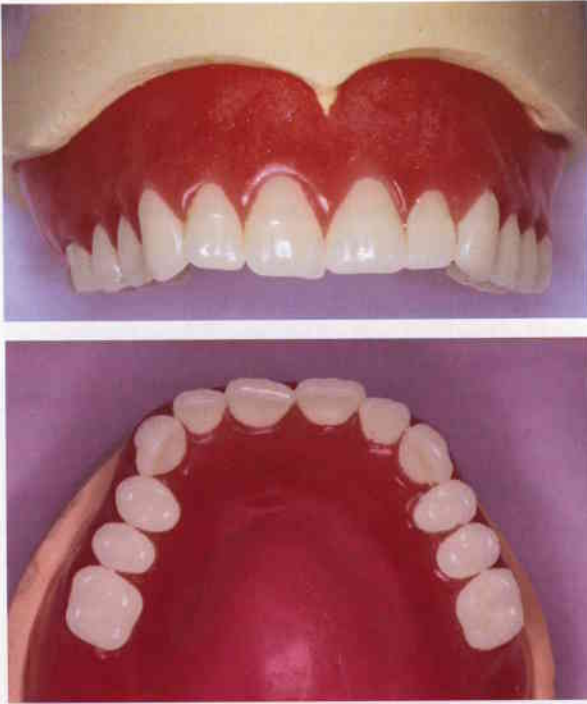


Fig. 4.3. *Above:* An anterior view of a masculine arrangement of the upper anterior teeth. *Below:* An occlusal view of a masculine arrangement of the anterior teeth

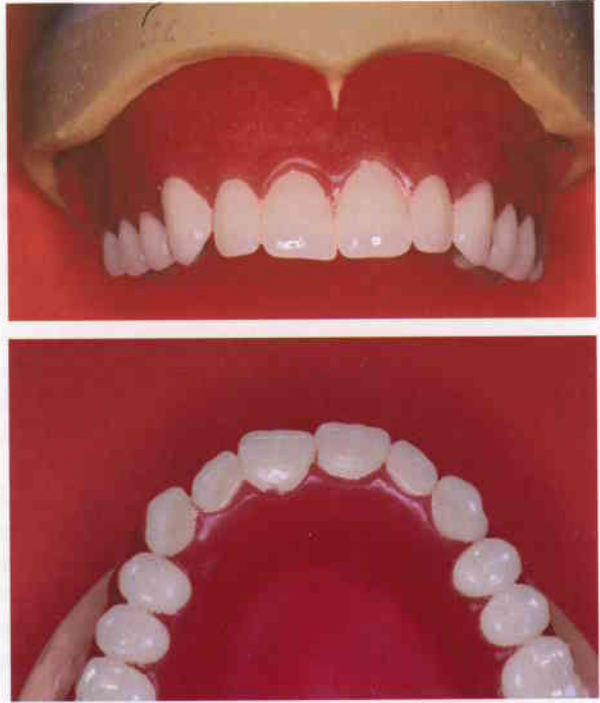
ment of anterior teeth is to harmonize with the face, the anterior teeth should also be arranged symmetrically (Fig. 4.2). Some patients prefer asymmetries, and this can be discussed and agreed with the patient.

Hyde et al. (1999) showed that neither dentists nor technicians could distinguish gender when presented with casts of the anterior teeth from young dental students. There is some evidence in the literature for sexual dimorphism in the width of human mandibular canines, but these differences are very subtle (Anderson and Thompson 1973). Despite this, there may be some subjective features about tooth arrangement that patients identify as either "male" or "female" (Fig. 4.3a, b; Fig. 4.4a, b).

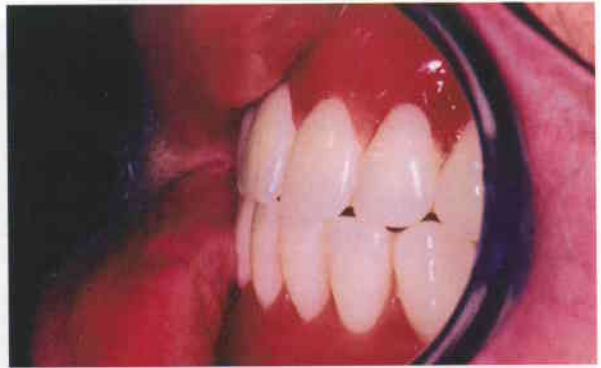Attention should be drawn to the amount of lip support, the coincidence of the upper and lower centre lines, and the angulation of the teeth. The amount of anterior tooth visible when the patient smiles should be assessed. With small teeth or a short upper lip, the flange may be visible when the patient smiles and may require thinning. Alternatively, either the position of the occlusal plane or the labial position of the anterior teeth may have to be altered.

From a mechanical viewpoint, maximum stability of the lower denture requires the fossae of the lower posterior teeth to be in line with the centre of the lower ridge and the palatal cusps of the upper teeth to occlude with those fossae. Where the mandible is prominent, the upper anterior teeth are set into an incis-

**Fig. 4.4.** *Above:* An anterior view of a feminine arrangement of the anterior teeth. *Below:* An occlusal view of a feminine arrangement of the anterior teeth



**Fig. 4.5.** In general the artificial teeth should be placed in the position previously occupied by the natural teeth, but one exception is the Angle's class III malocclusion. In this situation, the patient's upper teeth are positioned forwards to contact the lower incisors. The appearance of the upper proclined teeth can be more accurately assessed on the articulator if a facebow transfer registration is used to mount the casts



al edge-to-edge relationship with the lower teeth, avoiding excessive proclination of the upper teeth (Fig. 4.5). Often an additional lower incisor tooth may need to be incorporated into the lower trial denture, because of the size discrepancy between the arches.

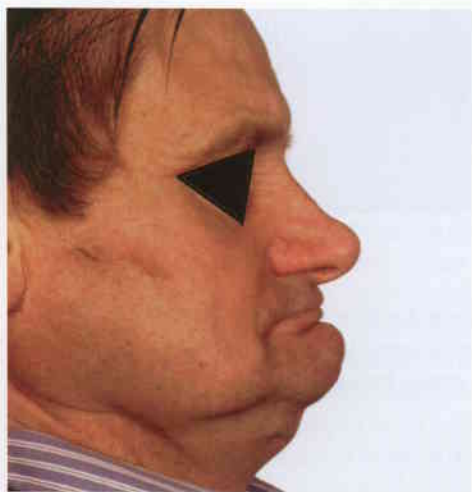


## Horizontal and Vertical Jaw Relationship

The interocclusal clearance is the space between the occlusal surfaces of the teeth at rest assessed with the lips lightly touching and with the lip musculature relaxed. According to some authorities, when the face is pleasing to the eye, the distance from the pupil to the lip commissure is 1.618 times the distance from the lip commissure to the base of the chin (Levin 1978). The factor 1.618 is the number phi ( $\phi$ ), or golden ratio, a number which occurs widely in art and in nature and has significance in fivefold symmetry. The golden ratio may or may not have great aesthetic significance. Certainly, the effect of a reduced lower facial height as a result of overclosure can detract from facial appearance, causing eversion of the lower lips with prominence of the labiomental groove (Fig. 4.6). The patient may have a prematurely aged appearance. As well as the effects on appearance, an increased interocclusal clearance can cause cheek biting, temporomandibular joint dysfunction and poor masticatory function.

The intercuspation of the posterior teeth is assessed when the mandible is in the retruded jaw relationship. This position of maximum intercuspation should be identical to that on the articulator. The interocclusal clearance should also be measured and compared with the patient's existing dentures. The interocclusal clearance should normally be in the range 2–4 mm, but where it has been excessive in the patient's old dentures it may be wiser to accept a compromise reduction of 3–5 mm.

Where the horizontal relationship has been incorrectly recorded, and the interocclusal clearance is satisfactory, the lower posterior teeth are removed and replaced with a wax rim. Where the position of the upper occlusal plane is satisfactory, but the interocclusal clearance is excessive, wax can be placed over the lower teeth. In both cases, the horizontal jaw registration is re-recorded using wax or



**Fig. 4.6.** In occlusion, this patient has the appearance of an Angle's class III malocclusion, but this is caused by overclosure of the dentures

a bite registration paste. If there are errors in the horizontal jaw relationship and the position of the occlusal plane, the clinician may wish to re-record the jaw registration using the wax occlusal rims used previously.

The clinician must also assess the degree of occlusal balance and articulation of the try-in on the articulator and in the patient's mouth. However, the poor stability of the wax try-in can render the oral assessment of occlusal balance very difficult.

## Developing Balanced Articulation with Anatomical Teeth

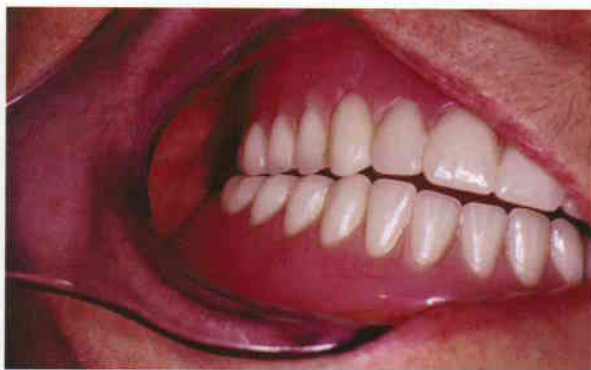Opening of the mandible involves a hinge rotation of the head of the condyle in the lower joint compartment, followed by a forward translation onto the articular eminence. There is, therefore, a steep downward movement of the mandible as the condyle moves over the articular eminence.

In order to maintain balanced articulation during lateral movements, the opposing cuspal inclines of the anatomical teeth on the balancing side must be increased. The cuspal inclination then compensates for the downward movement of the condyle on the balancing side with the result that the posterior teeth can remain in contact. On the working side, the condyle rotates and does not move down the articular eminence. Thus, the condylar guidance is  $0^\circ$  and the working side cuspal angles are shallow (Fig. 4.7). In producing a shallow cusp angle on the working side and a steeper angle on the balancing side, the molars must be inclined outwards to produce a lateral compensating curve.

By inclining posterior teeth buccally, different effective cusp angles can be provided for the balancing and working side contacts. The degree of lateral inclination of the contacting cuspal slopes on the balancing and working side are dependent on how close the teeth are to the condylar mechanism of the articulator, and the size of the incisal and condylar guidances.

The factors that influence balanced articulation are the condylar guidance, the incisal guidance, the cuspal angles of the posterior teeth, the orientation of the

Fig. 4.7. Movement of the mandibular posterior teeth to the patient's right side (working side) occurs in a nearly horizontal path, whereas the teeth on the patient's left side (balancing side) move downwards at an angle of about  $20^\circ$



occlusal plane and the degree of curvature of the compensating curve (Hanau's factors). Cusp angles of anatomical posterior teeth are typically about  $23^\circ$  (e.g. Enigma and Natura, Schottlander, Letchworth, UK).

The incisal guide angle is the incline provided by the anterior guide on the articulator. Where there has been an anterior try-in of maxillary and mandibular teeth, the incisal guidance has been accepted and is automatically fixed unless the anterior teeth are moved.

### Articulation with Cuspless Posterior Teeth

Cuspless teeth are easy to position in the trial denture, especially as they are often used in those patients who do not require balanced articulation. However, a close approximation to occlusal balance can be achieved if the articulator is set with a negative incisal guidance angle. At certain points, working and balancing cusp inclines will coincide. For example, if the condylar guidance is set at  $30^\circ$  and the incisal guidance at  $-15^\circ$ , then at the anteroposterior midpoint of the articulator, the balancing angle will be  $+7.5^\circ$  (mean of  $30^\circ$  and  $-15^\circ$ ) and the working side angle  $-7.5^\circ$  (mean of  $0^\circ$  and  $-15^\circ$ ). The discrepancy between the working and balancing side angles is the sum of the angles, i.e.  $0^\circ$ . However, balanced articulation will only occur at the midpoint and the occlusal discrepancy increases the further one moves away from this position. The effect of providing a negative incisal guidance angle improves the stability of the denture with cuspless teeth, but the upward movement path of the anterior teeth necessitates an anterior open bite and poor aesthetics (Figs. 4.8 and 4.9).

### Articulation in Lingualized Occlusion

For the upper denture,  $33^\circ$  posterior teeth are used (Optiform Posteriors, Enta, Bergen op Zoom, Netherlands). Though the lower teeth have a shallower cuspal inclination, a good chewing efficiency is produced because of the high palatal cusp angle. The articulation is simplified because tooth contacts are limited to one per tooth, therefore setting the teeth is much simplified.

### Simple Hinge Articulators

In complete denture construction, these instruments relate the mandibular and maxillary casts together in one static position, the retruded jaw relation. They do not reproduce mandibular movements therefore balanced articulation is not possible.

Fig. 4.8. Using nonanatomical teeth, a negative angle on the incisal guide table and a 30° condylar guidance will produce an approximation to occlusal balance. The teeth will then move along a path with a centre of rotation above the articulator

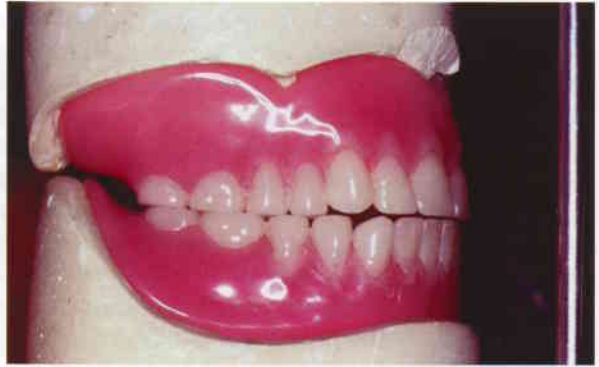
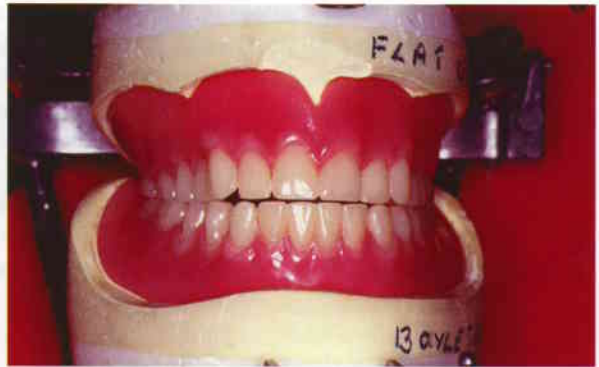
Fig. 4.9. The centre of rotation of nonanatomical teeth is above the articulator. An anterior open bite is therefore required because the mandibular anterior teeth move upwards during protrusion



## Average Value Articulators

These articulators have a fixed condylar guidance, and can provide satisfactory balanced articulation in the patient with “average” jaw size and movement patterns. One example is the Denar average value articulator (Automark), which has a 25° protrusive condylar guidance. The average value articulator permits lateral movements. An anterior incisal guide rod moves over an incisal guide plate to provide an opening movement. With anatomical tooth arrangements, the angle that the incisal guide plate makes with the horizontal is usually arranged to be about 0–10°. The occlusal surface of the upper wax rim is orientated to the horizontal by placing it on a removable table attached to the lower arm of the articulator.

Complete dentures constructed using average value articulators (which allow for articulation) have better function than those constructed using the simple hinge articulator as food is chewed more finely prior to swallowing (Mowlana and Heath 1991).

### *The Facebow*

Facebows are used with average value or adjustable articulators to obtain a record of the maxilla-glenoid fossa relationship. Many different types of facebow exist, but in general the facebow consists of a metal U-shaped bow, which can be adjusted so that its ends contact the skin over the glenoid fossa. A bite fork is attached to the upper wax rim and then connected eccentrically to the bow by means of a universal joint. The patient is centred in the facebow. An anterior reference point such as the lowest point of the bony orbit (orbitale) may be used to locate the occlusal plane in space. Where an orbital pointer is used, it is attached to the facebow by another universal joint.

The facebow has at least two functions:

1. The facebow can be used to record the relationship of the maxilla to the patient's hinge axis of rotation of the mandible. This relationship can be transferred to an average value articulator with the result that an acceptable reproduction of the patient's jaw movements can be obtained.
2. In the laboratory, the artificial teeth are usually set to a horizontal plane, but in the mouth the occlusal plane is angled nearly  $10^\circ$  to the horizontal in the anteroposterior plane. The result is that when the teeth are tried in, the incisors appear slightly retroclined. If a facebow is used to mount the secondary casts following the jaw registration stage, the angulation of the occlusal plane and the anterior teeth will be the same as in the patient's mouth.

### **Adjustable Articulators**

These articulators have an adjustable protrusive condylar guidance, often varying in the range  $0-60^\circ$ . One example is the Denar Mark II semiadjustable articulator, which has an adjustable condylar guidance and lateral translations (immediate side-shift adjustment of  $0-4$  mm and progressive side-shift of  $5-15^\circ$ ). The articulator settings can be adjusted for each individual patient by recording protrusive and lateral wax jaw registrations. However, due to mucosal compression there is an error of at least 1 mm in transferring a jaw registration from the edentulous patient to the articulator. When using protrusive occlusal records to set the condylar guidance, the mucosal compression can create considerable errors in the sagittal condylar guidance angle. The lateral translation of the mandible during lateral excursion has only a small influence on occlusal balance and so the use of complicated adjustable articulators is not recommended.

### **The Closest Speaking Distance**

This is a distance of about 2 mm observed between the incisor teeth when the patient pronounces sibilant words. An absence of this space indicates that the pa-



tient has too great an occlusal vertical dimension. This distance may be dependent on the position of the /s/ sound in the sentence (Howell 1986) and is highly variable in magnitude between dentate individuals. Experimental studies have found a great variation in this distance. It varied in the range 0–10 mm in a group of 208 dentate patients (Silverman 1951). Burnett (1994) found that in a group of 30 dentate subjects, the mean closest speaking distance was not significantly correlated with the mean postural interocclusal space. In addition, the postural interocclusal space was smaller than the closest speaking distance in the majority of patients.

However, both methods of measuring interocclusal clearance, based on either postural interocclusal measurement or the closest speaking distance, are useful. Other methods of assessing interocclusal clearance, such as those based on facial appearance, have little experimental support. McGee (1947) found that in some dentate subjects the distance from the pupil to the lips equals the distance from the nostril to the chin. Unfortunately, measurements such as these are variable and inaccurate when used in constructing complete dentures, and provide only the most general indication of the correct occlusal vertical dimension.

### Colouring the Labial Flange

The teeth are usually set in pink wax. Where necessary, brown waxes can be applied to the try-in flange in black patients to imitate the melanin pigmentation of the patient. In the processed denture, light-brown colour stains can also be used to pigment the flange so that it will blend with their oral tissues and skin colour. Kayon Denture Stains (Kay See Dental Manufacturing Company, Kansas City, Kan., USA) can be used to stain the denture flanges with a range of colours. They are incorporated into the denture during the processing stage and are therefore permanent. Final dentures for fair-skinned individuals can incorporate different shades of pink, veined and clear acrylic to build up a realistic colour of the labial flange.

### Postdam

The postdam is positioned on the palatal vibrating line, the junction between the mobile and the immobile areas of the palate. It can be difficult to locate in some patients, but the foveae palatinae can be used as a general guide to its position. The vibrating line can be marked in the mouth with denture relief cream, which is then transferred to the trial denture. The posterior edge of the trial denture is adjusted accordingly. The depth of the postdam should conform to the displaceability of the palatal tissues, which is best assessed with a ball-ended burnisher. The postdam should extend across the palate over the hamular notches and into the buccal sulcus. It should not have to conform to the classical Cupid's bow shape.



The tissues in the lateral region of the palate, medial to the ridge, are thickest due to the deep submucosal layer containing adipose, nervous and vascular tissues overlying the greater palatine neurovascular bundle. The postdam in this region can be up to 2 mm in depth. The depth of the postdam is minimal in the palatal midline area. In the sagittal plane, the postdam is shallow anteriorly and is at its deepest at the vibrating line, where it finishes abruptly.

## Undercuts

Bilateral bony undercuts will prevent denture insertion, but if the tissue is soft and displaceable denture insertion will not be prevented. The dentist should therefore inspect the undercut area in the mouth and on the cast and indicate to the technician the amount of blocking out necessary. By providing denture relief, the dentist may avoid having to adjust the denture extensively on insertion. Even with bony undercut, at least 1 mm of undercut is usually left on both sides so that some denture retention is provided. Using a surveyor, the undercut is blocked out on the cast with plaster prior to processing the denture in heat-cured acrylic resin. The flange may have to be thickened by the technician prior to processing the denture, so that when fitting the denture any adjustment by the dentist does not remove the flange completely.

Unilateral undercuts can often be used without blocking out the undercut. The patient quickly learns to rotate the denture into place. Large, fibrous tuberosities usually cause few denture retention problems. Their size may mean that it is difficult to position posterior artificial teeth in the space available without misalignment of the occlusal plane. Fewer teeth can be used. Alternatively, if the posterior fibrous ridges adversely affect the denture base stability, they can be surgically reduced in size.

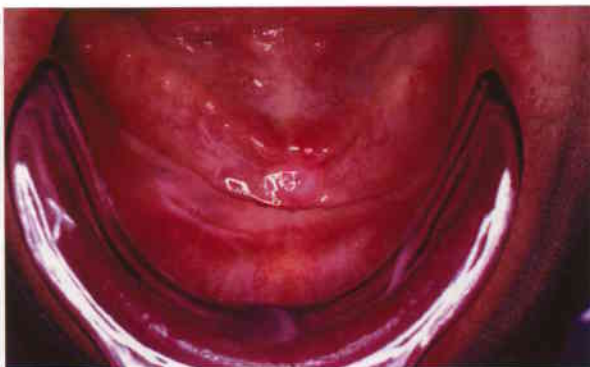## Providing Tin-Foil Relief

Often, the lower, anterior residual ridge is tender to palpation. Radiographic examination may reveal a sharp ridge. Similarly, the thin mucosa over a prominent mandibular or palatal torus, mylohyoid ridge or genial tubercle can be easily traumatized (Fig. 4.10). Prior to denture processing, thin tin foil can be glued to the cast over the area outlined by the dentist. The wax try-in is adjusted, fitted on to the cast and processed.

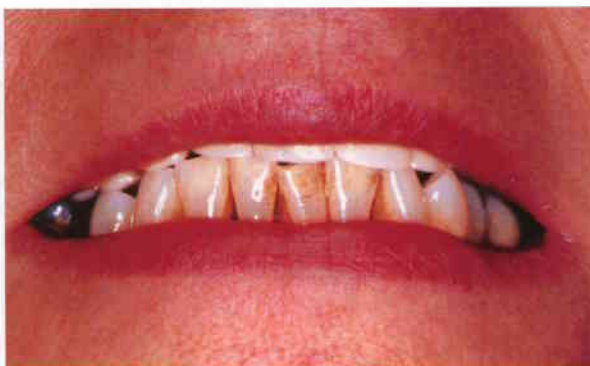## Liaison with the Laboratory

Major modifications will require the try-in to be sent back to the laboratory for resetting of the teeth. Unambiguous communication with the laboratory is essen-

**Fig. 4.10.** In the resorbed mandible, the genial tubercles are easily traumatized as the thin layer of mucosa overlying them is very thin



**Fig. 4.11.** Overeruption of the natural teeth opposed by a complete denture can adversely affect function and aesthetics



tial with clear written instructions and other appropriate information. For example, where the centre line of the try-in has to be changed, the new centre line must be indicated by replacing the incisor teeth with wax and adjusting the wax accordingly. Alternatively, the new centre line can be drawn on the teeth with a wax pencil. Studies that have audited denture prescription in Britain have found that dentists have major deficiencies in communication with their laboratory technicians. Basker et al. (1993) showed that a postdam was provided by dentists in only 16% of the 50 trial dentures scrutinized. The wax occlusal rims indicated the incisal relationship in only 50% of cases.

## The Complete Upper Denture

When constructing an upper complete denture to an existing lower natural dentition, overeruption of the natural teeth can compromise the denture appearance (Fig. 4.11). The upper denture teeth can appear small and artificial. In order to make the upper anterior teeth more visible, the incisal level may be brought be-

low the upper lip, which increases the overbite. However, the upper denture may become unstable as it is then displaced during protrusive movements of the mandible. Extending the upper denture base around the tuberosities to the hamular notches and providing sufficient overjet can prevent denture displacement. An alternative solution may involve reduction in the height of the lower incisors by judicious grinding of their incisal edges. It is never satisfactory to permit more of the denture teeth to show by obliterating the interocclusal clearance because the natural teeth will remain in continuous occlusal contact with the denture and transmit damaging forces to the edentulous ridge. The mucosal tissues under the denture will inevitably feel painful and sore.

Where the lower posterior natural teeth are severely tilted or overerupted, irregularities in the occlusal plane can cause denture instability especially during protrusive movements. Extracting severely misplaced lower molar teeth can have the disadvantage that a lower free-end saddle is created with increased instability of the upper denture. A better solution may be to crown the lower molar teeth, reducing in particular the prominent distal cusps and building the mesial cusps into occlusion. The best result is obtained when, at the try-in stage, the upper denture teeth are set up against the waxed-up crown (Stephens 1970).

Ideally, the upper denture should occlude with the natural tooth surfaces so that occlusal forces are transmitted vertically and not horizontally. This may be possible by selective grinding of the natural teeth and/or provision of a partial denture, which will reduce the displacing forces. If a lower metal framework is used, onlays over the lower molar teeth can even the occlusion.

## The Complete Lower Denture

Constructing a successful lower denture with opposing natural upper teeth can be very difficult. Pain and severe mandibular bone resorption often results from the transmission of large occlusal forces to the small mandibular ridge. However, incorporating a resilient liner in the lower denture and extending it over the maximum available denture-bearing area can reduce the pressure applied to the ridge. These linings have a relatively short life and require regular review and replacement.

Balanced articulation is desirable, but often difficult to achieve. Fortunately, the mandibular anterior teeth are usually the last teeth in the dentition to be lost, so this situation only occurs rarely.

## References

- Anderson DL, Thompson GW (1973) Inter-relationships and sex differences of dental skeletal measurements. *J Dent Res* 52:431
- Basker RM, Ogden AR, Ralph JP (1993) Complete denture prescription - an audit of performance. *Br Dent J* 174:278-284
- Brisman AS (1980) Esthetics: a comparison of dentists' and patients' concepts. *J Am Dent Assoc* 100:345-352
- Brodbelt RHW, Walker GF, Nelson D, Seluk LW (1984) Comparison of face shape with tooth form. *J Prosthet Dent* 52:588-592
- Burnett CA (1994) Reproducibility of the speech envelope and interocclusal dimensions in dentate subjects. *Int J Prosthodont* 7:543-548
- Howell PGT (1986) Incisor relationships during speech. *J Prosthet Dent* 56:93-99
- Hyde TP, McCord F, Macfarlane T, Smith J (1999) Gender aesthetics in the natural dentition. *Eur J Prosthodont Rest Dent* 7:27-30
- Levin EI (1978) Dental aesthetics and the golden proportion. *J Prosthet Dent* 40:244-252
- McGee GF (1947) Use of facial measurements in determining vertical dimension. *J Am Dent Assoc* 35:342-350
- Mowlana F, Heath MR (1991) Swallowing thresholds using dentures made on different types of articulator. *J Oral Rehab* 18:413-420
- Silverman MM (1951) Accurate measurement of vertical dimension by phonetics and the closest speaking centric space. Part I. *Dent Digest* 57:261-265
- Stephens AP (1970) Full dentures which occlude with natural teeth. *Dent Pract* 21:37-42

---

## 5 Fitting the Processed Denture

|                                          |    |
|------------------------------------------|----|
| Remounting Procedures .....              | 81 |
| Occlusal Adjustment                      |    |
| Using an Average Value Articulator ..... | 81 |
| Occlusal Adjustment Using a Facebow      |    |
| Registration and Articulator .....       | 81 |
| Denture Retention .....                  | 83 |
| Aesthetic Appearance .....               | 83 |
| Patient's Instruction Leaflet .....      | 83 |
| Denture Fixative .....                   | 84 |
| References .....                         | 84 |

It is necessary to eliminate any premature occlusal contacts to ensure that the patient has maximum comfort as they learn to control the new dentures. Slight occlusal errors may have been produced during the processing of the dentures, which may require them to be remounted on the articulator. After processing, but before the removal of the dentures from their casts, they are returned to the articulator. This is easily accomplished by using split-cast mounting techniques, which allow easy location and removal of the cast from its mounting plaster on the articulator. The technician needs to be instructed about this requirement when articulating the casts prior to setting the teeth. Split-cast mounting is carried out in the laboratory, by notching the base of the cast and applying separating medium just before articulating the casts. The cast can be removed from the mounting plaster and reattached using cyanoacrylate glue.

The cast is easily separated from the mounting plaster and is flaked with the try-in. After processing the dentures, the casts and dentures are removed intact and reattached to the articulator mounting plaster. Premature occlusal contacts are then eliminated by selective tooth grinding.

When the finished denture is returned from the laboratory, it is disinfected and then examined. Sharp edges or acrylic pearls on the denture fitting surface are removed with a dental stone burr. A sharp postdam is smoothed with a dental stone. The dentures are inserted and checked for adequate retention and stability. If the denture engages bilateral bony undercut, then insertion may not be possible without causing the patient considerable pain and discomfort. Pain usually occurs during insertion and removal of the denture. The location of these undercuts can be detected using pressure relief cream. A thin layer of this low viscosity paste is applied to the undercut surface of the denture and the denture inserted gently. When resistance is met, the denture is removed and examined. Where the paste has been wiped off the denture is eased. It is important to avoid wiping the paste off the denture during careless insertion, so the lips and cheeks are lifted out of the way.

By far the commonest cause of occlusal errors in the finished denture is a failure to have recognized the error at the earlier try-in stage. If the patient closes together with a small occlusal error present, the try-in tends to rotate after the moment of first contact, with the result that the teeth appear in even occlusion. Using a try-in with a retentive, stable acrylic baseplate assists in detecting these occlusal errors.

Where there is insufficient interocclusal clearance, one (or both) dentures must be remade. This is because grinding the teeth to achieve 2–4 mm of interocclusal clearance will eliminate the cuspal contour of the teeth. The denture can be quickly converted into a close-fitting special tray with removal of undercuts and border moulding with tracing stick compound. An impression is taken inside the denture using zinc oxide/eugenol and then cast up. The jaw registration and try-in are repeated using the new cast.



## Remounting Procedures

### *Occlusal Adjustment Using an Average Value Articulator*

Remount procedures allow the dentures to be returned to the articulator for occlusal adjustment. This is preferable to performing occlusal adjustment at the chairside, where articulating paper is used to mark the retruded contact position and excursive movements. With the dentures remounted on the articulator, lateral excursions are easily obtained and interfering contacts are detected more easily. Remounting of the dentures requires that either an average-value or semiadjustable articulator be used to examine the lateral and protrusive occlusal contacts. Using a simple hinge articulator is not satisfactory, as lateral excursions are not possible. Where an average-value articulator is to be used, the retruded contact position is recorded intraorally using soft wax. The upper denture is articulated so that the pin, which passes through the incisal guide rod, touches the midline at the upper incisal edge. The lower denture is attached to the articulator with plaster of Paris, ensuring that the occlusal plane is horizontal and parallel to the base of the articulator. When the plaster has set, the wax is removed between the occlusal surfaces of the teeth and the occlusal adjustment is carried out. When the wax is removed, the teeth then contact, rotating about the condylar axis of the articulator.

### *Occlusal Adjustment Using a Facebow Registration and Articulator*

The facebow transfers the relationship of the maxilla and the patient's intercondylar axis to the articulator's hinge axis. At either end of the facebow are the condylar rods which are placed over a point on the skin 10 mm anterior to a line joining the central part of the tragus with the outer canthus of the eye (Gysi 1910). This provides an acceptable arbitrary hinge axis. The facebow is adjustable to accommodate variable intercondylar distances. A facebow is used to record the relationship of the upper denture to the patient's mandibular hinge axis and transfer this to an articulator, using the hinge axis of the articulator as a reference. If a facebow is used to locate the upper denture to the articulator, subsequently removing the occlusal wax allows the teeth to contact by rotating about an arc of closure identical to that of the patient. A facebow is therefore often used to remount the processed dentures on an articulator for the correction of occlusal errors.

*Practical Procedures: Recording the Maxilla to Mandibular Hinge Axis Relationship.* Using the facebow preparatory to remounting the dentures, softened wax is applied to the bite fork which is then attached to the teeth of the upper denture. The patient closes together and holds the bite fork in position with the stem protruding forwards. The universal joint of the facebow is slid over the stem of the fork and tightened with the condyle slides positioned over the arbitrary hinge ax-

is marks on the patient's skin. The condyle slides are released and the facebow is then removed. To enable the lower teeth to be mounted on the articulator, a separate wax record is made. Wax is placed on the lower posterior teeth and a recording is made with the patient closing together in the retruded jaw relationship. Excess wax on the buccal surfaces of the teeth is removed to allow a clear view of the teeth coming together in the correct relationship. It is important to avoid penetration of the wax and cuspal contact so that mandibular deviation during closure is prevented.

There are other facebows which differ in their manner of use from this general description. For example, the Denar Slidematic facebow uses the external auditory meatus as an arbitrary hinge axis location. The facebow is aligned with a horizontal reference plane. After the clinical facebow measurement has been taken, only the transfer jig is mounted on the articulator.

*Laboratory Occlusal Adjustment Procedures.* In the laboratory, undercuts in the denture fitting surface are blocked out with damp cotton wool and the upper denture is mounted with plaster using the facebow recording. The occlusal plane of the denture should be midway between the arms of the articulator. When the plaster has set, the facebow and bite fork are removed from the denture. Using the wax registration previously recorded, the lower denture is attached to the upper denture. After inverting the articulator, severe undercuts on the fitting surface of the lower denture are blocked out using damp cotton wool and the lower denture is mounted to the lower arm of the articulator with plaster. When the plaster has set, the wax record is removed from between the teeth and the dentures examined for occlusal discrepancies. Selective grinding is now carried out.

The first objective is to remove premature contacts in centric occlusion (by grinding the cusp if it is in premature contact in lateral excursive movement and deepening the fossa if it is not). The second objective is to achieve balanced occlusion in lateral excursions without jeopardizing the vertical height of the dentures. With working side prematurities, the buccal cusps of the upper teeth and the lingual cusps of the lower teeth are ground (the BULL rule). With balancing side prematurities, the buccal cusps of the lower teeth are adjusted. Lastly, if there are premature posterior tooth contacts in protrusive movement, the buccal cusps of the upper teeth and the lingual cusps of the lower teeth are ground. The dentures are polished and returned to the patient.

*Physiological Considerations.* Due to short-term variations in the fluid content of the tissues around the condyle, measurement of the retruded contact position can only be duplicated within the range 0.1 to 0.4 mm, even under idealized clinical conditions (Wiskott and Belser 1995). Some other factors such as neuromuscular adaptation, altered pressure on the temporomandibular joint or settling of the denture into the soft tissues may cause slight changes in the denture occlusion after the dentures are fitted (Utz 1996). Further occlusal adjustment is therefore necessary after 1–3 weeks of denture wear.

## Denture Retention

This is assessed by gently attempting to pull the dentures away from the tissues. Over- and underextension of the denture are most often the causes of poor denture retention in function. Manipulation of the cheeks by gently moving them backward and forward and up and down can detect and relieve areas of overextension.

A deficient postdam or underextension in the lateral tuberosity area will allow the upper denture to be displaced downwards in the posterior region. Greenstick composition is applied to the areas of underextension and with appropriate border moulding movements the correct extension produced. The laboratory can then convert the composition addition into self-curing acrylic. This is done by pouring a plaster model into the fitting surface, carefully blocking out undercuts with damp cotton wool. The greenstick composition is removed and a postdam is cut in the cast. Self-curing acrylic is added, cured and polished.

## Aesthetic Appearance

The patient has previously approved the appearance of the dentures at the try-in stage. The shape of the flanges may have been changed during the final waxing-up of the teeth prior to processing, but excessive fullness of the flanges can be corrected easily by grinding. Requests for major changes in the position or colour of the teeth will often require the dentures to be remade. This can result from radical changes in the patient's appearance produced by the new dentures. As well as the position of the teeth themselves, the vertical level of the occlusal plane, occlusal vertical dimension, overbite and overjet all influence the amount of anterior tooth visible.

A number of staining systems are available to produce a more natural appearance to the finished denture. One example is the Minute Stains System (George Taub Products, Jersey City, N.J., USA), which has seven different pigments suspended in varnish solvent. Mixtures of pigments are applied to the artificial teeth with a paintbrush and when a satisfactory result has been obtained it is protected with a clear glaze. The dentist applies these stains to the denture at the chair-side, so that the patient can evaluate the appearance. The stain tends to be removed during wear over 6–12 months.

## Patient's Instruction Leaflet

Written and verbal instructions can educate the patient about dentures, ensure good denture hygiene and increase patient satisfaction. Unfortunately, patients can often decide on the success or failure of treatment in the first few minutes of wearing the new dentures unless counselled carefully before the dentures are in-

serted. Patients need to know what difficulties they might expect to have with new dentures. Speech may be difficult for a short period following denture insertion, exacerbated by excess salivation. Eating may cause some discomfort or mild ulceration in the early stages, but is made easier with nonsticky food. Patients are given a review appointment in about a week. They should also be informed that a regular annual review to check on the health of the oral tissues is essential.

The denture should not be worn at night, as this will predispose to denture stomatitis. At night, the denture should be cleaned and stored in water to prevent uneven shrinkage. In the event of the dentures causing pain, they should be removed and placed in water. The painful area is easier to detect if the patient wears the denture on the day of the appointment.

### Denture Fixative

Denture fixative is a useful patient aid to assist with denture retention, especially when the patient has had no previous denture-wearing experience. It improves function in those with unrealistic demands or with compromised denture retention, e.g. those with a dry mouth or atrophic residual ridges. In a survey of patients attending Adelaide Dental Hospital, South Australia, a high proportion (20.5%) did not know of the existence of denture fixatives and only a small percentage (6.9%) used them on a regular basis (Coates 2000). Denture fixative products cannot make ill-fitting dentures suitable, but they are effective in assisting the new denture-wearer to quickly adapt (Ghani et al. 1991). To be fully effective fixative must be applied in a thin layer which does not upset occlusal balance.

### References

- Coates AJ (2000) Usage of denture adhesives. *J Dent* 28:137-140
- Ghani F, Picton DC, Likeman PR (1991) Some factors affecting retention forces with the use of denture fixatives in vivo. *Br Dent J* 171:15-21
- Gysi A (1910) The problem of articulation. *Dent Cosmos* 52:1-19
- Utz KH (1996) Studies of changes in occlusion after the insertion of complete dentures. Part 1. *J Oral Rehab* 23:321-329
- Wiskott HWA, Belser UC (1995) A rationale for a simplified occlusal design in restorative dentistry: historical review and clinical guidelines. *J Prosthet Dent* 73:169-183

---

## 6 The Review Appointment

|                                                                              |    |
|------------------------------------------------------------------------------|----|
| History of the Complaint .....                                               | 86 |
| The Painful Denture .....                                                    | 86 |
| Persistent Pain .....                                                        | 89 |
| Occlusal Loading of the Oral Tissues<br>and Resilient Lining Materials ..... | 90 |
| Properties of the Different Types<br>of Resilient Lining Materials .....     | 91 |
| Other Causes of Persistent Pain .....                                        | 91 |
| Defective Speech .....                                                       | 91 |
| “Unable to Chew Food Properly” .....                                         | 92 |
| Vague Symptoms .....                                                         | 92 |
| Burning Mouth Syndrome .....                                                 | 93 |
| Summary .....                                                                | 93 |
| References .....                                                             | 94 |

Much research has been undertaken in an effort to explain why some patients have extreme difficulty in wearing complete dentures successfully. The technical quality of the dentures is of the utmost importance, but research is divided on the importance of medical and psychological factors (Brunello and Mandikos 1998; Beck et al. 1993). Older people take longer to adapt to new dentures, but questionnaires, in-depth interviews and personality assessments have all been unsuccessful in identifying any other consistent factor that may predict a patient's inability to tolerate dentures.

Various audit studies have been carried out of dentures constructed by dental laboratories in general dental practice. The main technical faults can be summarized as excessive reduction of the denture border and large changes in vertical dimension (Barsby et al. 1995).

If too great an occlusal vertical dimension is provided, the patient may complain of continual clattering of the teeth or generalized pain which increases during the day (Jeganathan and Payne 1993). During mastication, the patient may find that there is not enough room for the food. Reduction of the interocclusal clearance can be prevented during processing of the denture by investing the trial denture in plaster with a stone matrix over the teeth. The stone matrix prevents tooth movement, but deflasking the denture can be more time consuming.

## History of the Complaint

Time spent obtaining a detailed history of the complaint can often prevent misdiagnosis, incorrect treatment and exacerbation of the patient's problem. Therefore, typical questions to a patient about their loose dentures may include:

1. Are both upper and lower dentures loose or just one of them?
2. Are the dentures loose at rest or when eating?
3. Does movement of the lips, cheeks or tongue cause denture looseness?

Looseness of dentures may also be associated with a host of other complications such as clicking of the teeth and pain. Patients may have too-high expectations of the function of their dentures, but this usually becomes obvious from the results of the questioning.

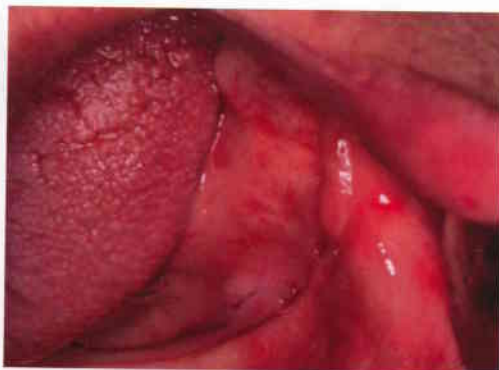
The whole of the patient's mouth should be examined and any erythema or ulceration noted and related to the fitting surface, the occlusal surface or the polished surface of the denture. Denture adjustment kits containing a variety of burs are available (from Henry Schein, Melville, New York, USA).

## The Painful Denture

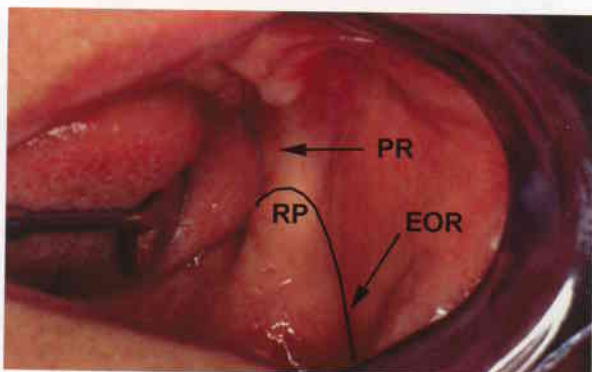
Overextension of the denture periphery can cause ulceration and pain and is often caused by inadequate moulding of the periphery at the impression stage



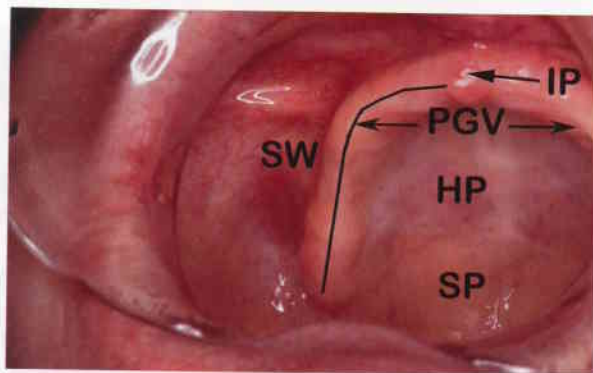
**Fig. 6.1.** An overextended lower denture has caused lingual ulceration and an erythematous line on the cheek. Reduction of the denture periphery eliminated the pain



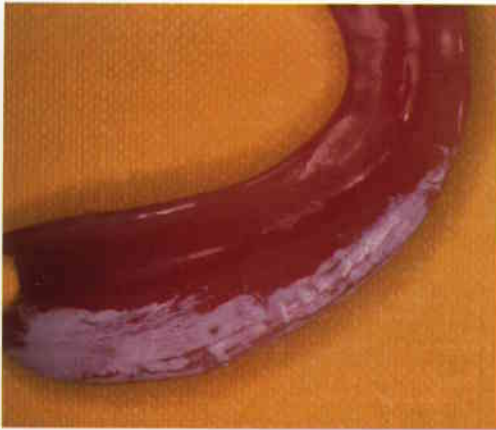**Fig. 6.2.** The normal anatomy of the lower edentulous ridge (*PR* pterygomandibular raphe; *EOR* external oblique ridge; *RP* retromolar pad)



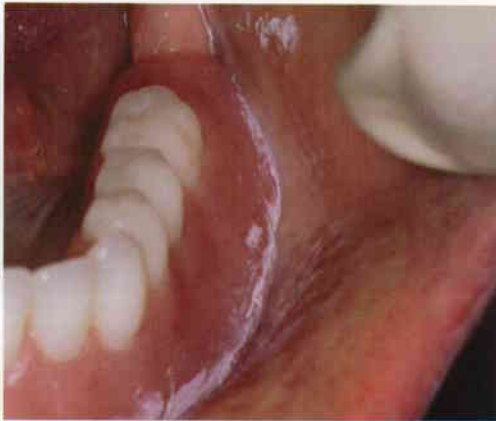**Fig. 6.3.** The normal anatomy of the upper edentulous ridge (*IP* incisive papilla; *HP* hard palate; *SP* soft palate; *SW* sulcus width; *PGV* palatal gingival vestige)



(Fig. 6.1). Where the lower denture is extended further buccally than the external oblique ridge then the denture will be unstable and unretentive (Fig. 6.2). The posterior limit of the lower denture is the junction of the mobile and immobile tissues at the middle of the retromolar pad. Extending the denture further posteriorly over the pterygomandibular raphe will result in ulceration of the tissues



**Fig. 6.4.** A petroleum jelly/zinc oxide/eugenol disclosing paste can be used to reveal pressure spots and areas of overextension

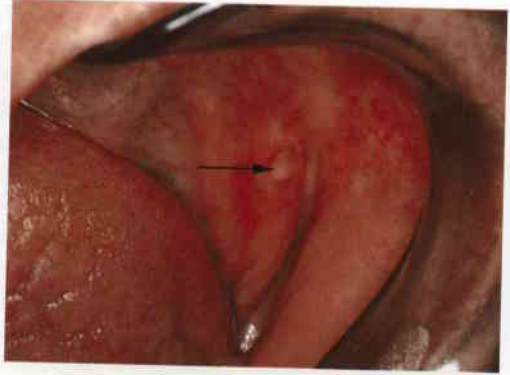


**Fig. 6.5.** The paste is applied to the denture and carefully inserted in the patient's mouth. Border moulding can reveal areas of overextension

and difficulty in swallowing. Similar swallowing difficulties are experienced if the upper denture is extended onto the soft palate area (Fig. 6.3).

Alternatively, irregularities on the fitting surface of the denture or too-deep a postdam on the upper denture may cause excessive pressure to the underlying mucosa. A thin paste of zinc oxide and petroleum jelly applied to the fitting surface of the denture can be used as a disclosing paste to reveal pressure spots (Fig. 6.4). The denture is placed in the patient's mouth and if border moulding is carried out, areas of overextension are also disclosed (Fig. 6.5). "Fit Checker" (GC Corporation, Tokyo, Japan) is a white paste material that can also be used to detect local areas of the fitting surface of the denture applying excessive mucosal pressure. The material is mixed and applied to the denture fitting surface in an even layer, and the denture is seated with evenly applied hand pressure. The material sets to a thin, white rubbery film. Pressure spots can be marked with a pencil mark, the film removed and the denture adjusted. Unfortunately, patients with

Fig. 6.6. Cheek biting resulting from an insufficient buccal overjet. The ulcerated mucosal tissue (*arrow*) was nipped between the opposing occlusal surfaces of the buccal teeth



denture-induced ulceration associate the problem with the “fit” of the denture, but the denture occlusion must be considered prior to any adjustment, especially when there is pain and inflammation over the residual ridge area.

If the recorded retruded contact position does not coincide with intercuspal position, then occlusal trauma will result. Lawson (1959) and Hammond and Thompson (1982) found that in about one-third of the complete dentures they examined there was no coincidence of the retruded contact position and intercuspal position. This is a common denture fault. Remounting the dentures where a small error is present can allow easier occlusal adjustment.

Cheek biting (Fig. 6.6) is most usually the result of insufficient buccal overjet, when the tissues lie against the posterior teeth. During occlusion the tissues are nipped as they fall between the occlusal surfaces of the teeth. In a normal relationship, this can be corrected by reducing the buccal surface of the lower posterior teeth. In a crossbite relationship, the buccal surfaces of the upper teeth are reduced. Cheek biting can also occur with excessive interocclusal clearance.

If insufficient interocclusal clearance is provided with the new dentures, then the patient may complain of generalized pain under the dentures, “clattering” of the teeth during eating and muscle pain. They may be unable to approximate their lips properly during speech, so that pronunciation of sounds such as “p”, “b” and “m” are difficult.

## Persistent Pain

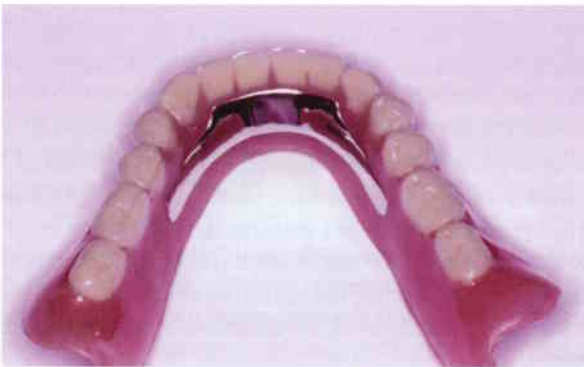One cause of persistent pain under lower dentures results from either a reduced denture-bearing area or an incorrect occlusion producing too high an occlusal loading. Extending the denture periphery onto the retromolar pad and into the distolingual sulcus can ensure that the denture has optimum support and retention. Complaints of a sore throat when wearing the dentures are usually the result of an excessive posterior lingual extension or an excessively deep postdam line on the maxillary denture.

If no overextension of the denture is present, reduction in the width and length of the occlusal table can reduce the loading which is applied to the lower residual ridge. Persistent pain can also result from an occlusal prematurity, or a lack of balanced articulation. Alternatively, a resilient liner may be incorporated into the lower denture. These materials undergo viscoelastic deformation on occlusal loading, thereby reducing the load applied to the ridge. Makila (1976) reported excellent success rates in individuals with chronic denture soreness who had a resilient liner provided in their lower dentures. These individuals had otherwise functionally acceptable dentures. Duncan and Clark (1985) also reported a high (70%) success rate in patients with chronic residual soreness by providing a lower resilient liner.

### *Occlusal Loading of the Oral Tissues and Resilient Lining Materials*

Different areas of the oral mucosa vary in their capacity to sustain occlusal load because of their differing structure. A hard acrylic denture base easily traumatizes prominent areas of thin mucoperiosteum, for example over the maxillary canine eminence, mylohyoid ridge or over a thin atrophic lower ridge. The region of the posterior palatal junction of the upper denture is rarely traumatized by occlusal load because the denture rests on a resilient submucosal layer of adipose and glandular tissue. Trauma in this region is usually related to a sharp or deep postdam.

Oral mucosa behaves in a viscoelastic manner. Under normal conditions, the shape of the oral mucosa is constantly changing as dentures apply intermittent occlusal loads throughout the working day. If a constant load is applied, there is a sudden elastic displacement, followed by a slower "creep" phase where tissue fluid is expressed from the tissues. If the load is released, immediate elastic recovery of the shape of the tissues is followed by a delayed recovery lasting many hours. In some patients, the mucoperiosteum covering the lower ridge provides little viscoelasticity, and resilient lining materials are employed in the dentures to



**Fig. 6.7.** A lower lingual cobalt-chromium strengthener may be necessary where provision of a resilient liner has weakened the denture

provide an artificial substitute. A minimum 2 mm thickness of resilient liner is necessary for it to provide the necessary degree of resilience. Where the thickness of the remaining acrylic denture base is compromised, fracture is likely unless a cobalt-chromium lingual strengthener is used (Fig. 6.7).

### *Properties of the Different Types of Resilient Lining Materials*

Two types of resilient lining material are generally used: the heat-cured silicones and the heat-cured acrylic types. None of the available materials can be considered to be permanent as after about a year they often become hard and cracked, contaminated with yeast or separated from the denture base. The acrylic-based resilient materials become harder with use as the plasticizer leaches out of the resin, whereas the silicone materials may attach poorly to the acrylic baseplate. Clinical opinion is divided as to what constitutes the ideal resilience, but in surveys of denture wearers, most patients express satisfaction with both types of resilient lining material.

Dentures incorporating resilient lining materials should be cleaned with soap and water rather than peroxide cleansers which attack their surface (Nikawa et al. 1994).

### **Other Causes of Persistent Pain**

Other causes of persistent pain under dentures may be associated with pathology, e.g. partly exposed roots. If pathology is suspected, e.g. due to the presence of a sinus or swelling, periapical radiographs are essential for accurate diagnosis. Anatomical abnormalities, such as a sharp residual ridge, mylohyoid ridge and genial tubercles can often cause pain, especially with occlusal pressure. Reduction of the fitting surface or placement of a resilient lining material can alleviate this problem. Where this is unsuccessful, surgical reduction may be required.

### **Defective Speech**

This fault arises through errors in either the occlusal vertical dimension, in the shape of the palatal polished surface, the arch form or from poor denture retention. Unfortunately, the most common response to a patient's speech problems is the arbitrary removal of acrylic from the palatal surface of the upper denture (Allen 1958).

The most common complaint is that the "s" sounds more like a "sh". In normal circumstances, the "s" sound is formed by a medial tongue groove, with a lateral tongue seal formed with the palatal acrylic (Farley et al. 1998). If the groove is incorrectly shaped, the "s" sounds like "sh". This results from placing the upper



teeth too far palatally or with excessive thickening of the denture base anteriorly which obliterates the narrow medial tongue groove. Central incisors should be placed with their labial surfaces 8–10 mm anterior to the centre of the incisive papilla. The same phonetic difficulty is produced if the tongue is unable to form a lateral seal with the posterior denture base.

Under- or overcontouring of the palatal surface of the denture can be revealed by brushing the palatal surface of the denture with a marker paste. The patient is asked to repeat the desired sound or recite a section of text and the palatal markings examined. Areas of overcontouring are revealed as the marking material is wiped off.

As already stated, an absence of freeway space can interfere with lip closure, and prevent bilabial sounds such as /b/, /p/, and /m/ (Kuebker 1984). However these sounds are also affected by errors in labiolingual incisor inclination. The labiodental sounds /f/ and /v/ can be used to assess the correct length and position of the maxillary incisor teeth (Martone 1963). The incisal edge of the upper incisor teeth should contact the junction between the oral mucosal and the transitional epithelium of the lower lip.

### **“Unable to Chew Food Properly”**

Patients may experience a temporary inability to masticate food to the same standard as with their old dentures. This can last a few months. It often occurs when the occlusal vertical dimension of the new dentures is increased resulting in an occlusal plane which is too high. The patient cannot easily position food on the occlusal surfaces of the teeth. However, inefficient mastication may be due to many other factors, e.g. loose or painful dentures.

Sometimes the patient complains that the dentures move over the supporting tissues during eating. This is corrected by ensuring that any displacement of the dentures by occlusal prematurities or overextension are minimized, while factors contributing to retention are maximized. A thick lingual flange or lingually placed lower molar teeth can encroach on the tongue space and cause the denture to be lifted during eating. Other displacing forces can arise from setting the lower teeth anterior to the residual ridge so that there is continual lip pressure forcing the denture up and backwards.

### **Vague Symptoms**

Tooth loss can be emotionally disabling for individuals rendered edentulous (Fiske et al. 1998). In a study by Davis et al. (2000), almost half (45%) of edentulous patients expressed difficulty in accepting their tooth loss. They expressed dissatisfaction with their dentures and found difficulty in coming to terms with the postextraction changes in facial appearance. It can be difficult in this research to



discriminate between the effect on the patient of tooth loss rather than the effect of wearing dentures or ageing. However, the general dental practitioner should be aware of the complex emotions that some patients will experience following loss of their teeth.

### ***Burning Mouth Syndrome***

Patients with this condition complain of severe, bilateral burning pain of the tongue, lips or palate. Examination of the area may not reveal any abnormality. Haematological investigations are used to exclude systemic disease such as diabetes mellitus, iron, folic acid and vitamin B deficiencies. Many medications which cause a reduced salivation should be considered as possible causes of burning mouth syndrome; tricyclic antidepressants and diuretics have been particularly associated with this condition. Candidiasis can be excluded using swabs of the fitting surface of the denture and smears of the affected mucosa. These organic causes of disease should be treated, when present.

Denture faults contributing to burning mouth syndrome include a lack of space for the tongue, which is the most frequently affected site. This occurs where the artificial teeth in the replacement upper denture are placed on the crest of the resorbed ridge, instead of buccal to the ridge. With burning of the anterior palate, relief of the nasopalatine area can be helpful. Other rare causes of burning symptoms include parafunctional habits (often caused by occlusal prematurities), and a high residual monomer content in the acrylic resin (eliminated by re-basing the denture with a prolonged cure of the acrylic).

Where the patient's symptoms fail to respond to this management regime, referral for specialist care should be considered.

### **Summary**

The most common denture complaints relate to pain, looseness, poor aesthetics and impaired mastication. Often complaints occur when the dentures have been designed without reference to the patient's existing dentures. Many patients who have worn dentures for many years have developed good muscular control of their dentures. Their lips, tongue and cheeks apply a retentive force to the polished surface of the denture in an unconscious, automatic manner. When constructing new dentures, changes such as in the shape of the polished surface or the flange extension may cause a loss of muscular control. The dentist may only suspect this explanation after the dentures have been constructed and the patient is experiencing considerable problems of adaptation. Patients who have had considerable difficulty with wearing recently provided dentures of adequate construction or elderly infirm patients may be suspected of having poor powers of adaptation. Using any of the "template denture techniques", their satisfactory old complete dentures should be copied with the minimum of change.

## References

- Allen LR (1958) Improved phonetics in denture retention. *J Prosthet Dent* 8:753-763
- Barsby MJ, Hellyer PH, Schwarz WD (1995) The qualitative assessment of complete dentures provided by commercial dental laboratories. *Br Dent J* 179:51-57
- Beck CB, Bates JF, Basker RM, Gutteridge DL, Harrison A (1993) A survey of the dissatisfied denture patient. *Eur J Prosthodont Restor Dent* 2: 73-78
- Brunello DL, Mandikos MN (1998) Construction faults, age, gender, and relative medical health: factors associated with complaints in complete denture patients. *J Prosthet Dent* 79:545-554
- Davis DM, Fiske J, Scott B, Radford DR (2000) A study of the emotional reaction to tooth loss. *Br Dent J* 188: 503-506
- Duncan JD, Clark LL (1985) The use of a soft denture liner for chronic residual ridge soreness. *J Am Dent Assoc* 111:64-65
- Farley DW, Jones JD, Cronin RJ (1998) Palatogram assessment of maxillary complete dentures. *J Prosthodont* 7:84-90
- Fiske J, Davis DM, Frances C, Gelbier S (1998) The emotional effects of tooth loss in edentulous people. *Br Dent J* 184: 90-93
- Hammond J, Thompson JC (1982) Diagnosis of complete denture difficulties. *Dent Update* 9:35-40
- Jeganathan S, Payne JA (1993) Common faults in complete dentures: a review. *Quintessence Int* 24:483-487
- Kuebker WA (1984) Denture problems: causes, diagnostic procedures and clinical treatment. Parts 3, 4. Gagging and speech problems. *Quintessence Int* 15:1231-1238
- Lawson WA (1959) Analysis of the commonest cause of full denture failures. *Dent Pract* 10:61-63
- Makila E (1976) Soft lining to relieve soreness beneath dentures. *J Oral Rehabil* 3:145-50
- Martone AL (1963) Clinical applications of functions in complete denture prosthodontics. 8. The final phases of denture construction. *J Prosthet Dent* 13:204-228
- Nikawa H, Iwanaga H, Hamada T, Yuhta S (1994) Effect of denture cleansers on direct soft denture lining materials. *J Prosthet Dent* 72:657-662

---

## 7 Domiciliary Treatment

|                                                          |     |
|----------------------------------------------------------|-----|
| Scope of Domiciliary Treatment .....                     | 96  |
| Denture Cleaning .....                                   | 96  |
| Denture Marking .....                                    | 98  |
| Clinical Technique .....                                 | 98  |
| Domiciliary Prosthetic Treatment .....                   | 99  |
| Denture Looseness .....                                  | 99  |
| Technique for Relining Upper<br>and Lower Dentures ..... | 100 |
| Template Dentures .....                                  | 100 |
| Repair of Dentures .....                                 | 103 |
| Stages Involved in Denture Repair .....                  | 103 |
| Other Causes of Fractured Dentures .....                 | 103 |
| References .....                                         | 105 |

Domiciliary treatment is the care of people in their regular place of habitation. As a result of mental or physical disability, patients may be unable to attend the dental surgery. The need for domiciliary treatment is great amongst the elderly who are known to have a poorer oral status than younger people. The prevalence of undernutrition is high among the elderly because patients who are unable to chew well may select poorly nutritious food that is easily masticated (Lamy et al. 1999). There is some evidence that providing elderly patients with dentures can reverse the impairment in nutrient intake (Appolino et al. 1997).

Many patients are medically compromised, and the dentist should take the necessary equipment to provide cardiopulmonary resuscitation: Ambubag, Lateral mask, Guedal airway, and oxygen. A mobile phone is essential, as this will allow an ambulance to be summoned. Naked flames should be avoided and other safety measures include using electrical equipment with a contact breaker.

### Scope of Domiciliary Treatment

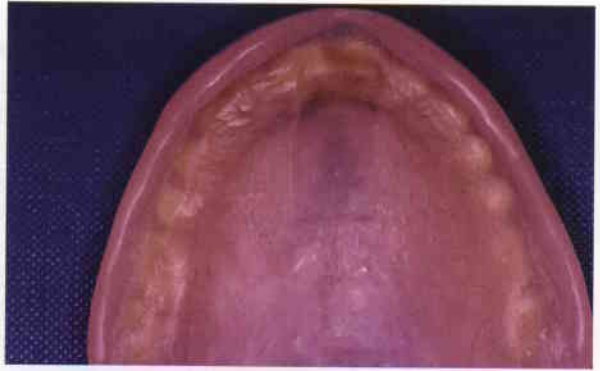Treatment provided in the patient's living quarters usually has to be of a limited nature because of the inadequate amount of equipment and materials available to the dentist. For example, it is not possible to take radiographs of the patient in their home. Most dentists provide domiciliary treatment limited to prosthetic treatment, extractions and simple restorations (Burke et al. 1995), that is treatment requiring low levels of patient maintenance.

While dentists may be limited in the scope of treatment they can provide in residential nursing homes, nursing staff can do much to improve the dental health of the elderly occupants. Nursing staff need constant encouragement as it has been shown that dental care for their patients is not high on their list of priorities. Prevention of caries and periodontal disease is extremely important and dental hygienists have a strong role to play. Simple measures, such as instruction in denture hygiene to nurses and patients, would also help to reduce the incidence of denture stomatitis in the elderly population.

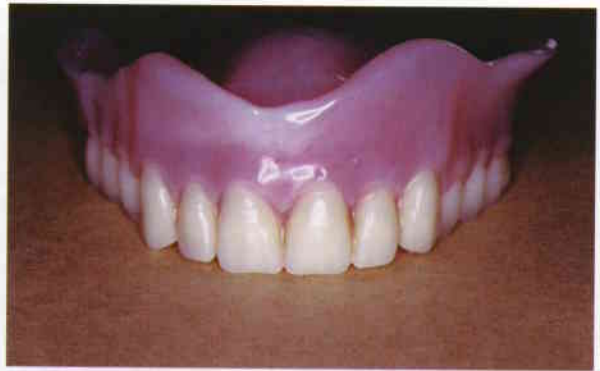### Denture Cleaning

In surveys of elderly people, only 40% of dentures were clean (Hoad-Reddick et al. 1990). Often, patients clean their dentures ineffectively because they use brushes with too-large a head. However, using only a small brush can take as long as 20 min to effectively clean dentures (Hutchins and Parker 1973). Nurses consider cleaning the dentures of those in their care an unpleasant task, but wearing thick rubber gloves might do much to alter this perception. The denture polished surface and teeth are easily cleaned because of their smooth surface. The irregular fitting-surface of the denture is the most difficult area to clean, but this part of the denture must be cleaned thoroughly if denture stomatitis is to be prevent-

**Fig. 7.1.** The narrow space between the palatal acrylic and the buccal flanges can be difficult to clean



**Fig. 7.2.** Whitening of the acrylic is produced by hot water



ed. Meticulous cleaning with a brush and soap is sufficient to remove plaque and soft debris from dentures, but many patients feel that dentures need to be soaked overnight in a proprietary cleanser before they feel clean. Soaking dentures overnight may suit those who are physically disabled, e.g. with arthritis and does at least ensure that the dentures are not worn for a period. Disabled patients may benefit from a variety of different sizes of brush handles for cleaning dentures. Where the patient has a high vaulted palate and narrow maxillary ridge, it can be difficult to clean the dentures because a brush-head will not fit into the space available (Fig. 7.1). Stain and calculus are more difficult to remove than denture plaque, but proprietary products are available.

Applying hot water causes whitening of the denture (Fig. 7.2). Although the exact mechanism is not fully understood, it is thought that the white appearance results from a difference between the refractive indices of the matrix and the polymerized beads. Bleaching agents are also known to produce the same effect.

## Denture Marking

Occasionally, it has been reported that nursing home staff collect and clean all of the patients' dentures together, with the wrong dentures being returned to the patients. To avoid this confusion, denture-marking kits are available. The patient's initials can be marked on the denture flange in some inconspicuous spot, but incorporating patient identification during denture manufacture is preferable.

Most studies have shown that very few patients object to having their dentures marked with some identification (Cunningham and Hoad-Reddick 1993). Despite this, surveys of elderly British denture wearers have shown that only a small percentage of them had any identification provided by the dentist (Fiske et al. 1986). In Sweden studies have shown that much higher percentages of elderly people have identification-marked dentures (Bengtsson et al. 1996).

### *Clinical Technique*

With the patient's permission, the posterior flange is abraded in one spot with some fine sandpaper and the debris removed. Using a fine graphite pencil, the initials of the patient's names are written on the roughened flange and a coat of clear acrylic, dissolved in chloroform, painted over the pencil marks. When this coat has dried a second coat is applied (Fig. 7.3). The solution is formed by dissolving 2.5 g of acrylic in 10 ml of chloroform. Chloroform is poisonous and denture marking is best done at manufacture by a dental laboratory technician using a fume cupboard. Chloroform is a very powerful anaesthetic agent. The chloroform solution should be kept in a dark bottle, as it tends to decompose in light yielding the highly poisonous compound phosgene.

In a clinical trial using this method, Heath et al. (1988) showed that 90% of initials covered with sealant remained clearly visible after 6 months. Painting chlo-

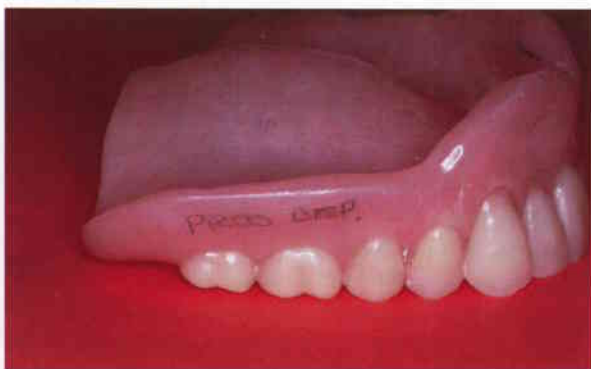

Fig. 7.3. A simple method of marking dentures with a patient's name. The identification mark is made in graphite pencil and protected with two layers of clear acrylic dissolved in chloroform



reform onto the acrylic surface of a denture will cause crazing of the surface, but Heath (1987) found no adverse effect on the transverse strength of the denture resin.

Other more permanent methods of denture identification have been described, involving incorporation of metal tags into the processed resin. Routine denture marking allows identification of disaster victims. To be able to identify victims of fire, stainless steel inserts must have been used since paper and thin aluminium inserts will not survive temperatures above 600°C.

## Domiciliary Prosthetic Treatment

Successful prosthetic treatment for the elderly and handicapped can be difficult because of the patients' residual ridge atrophy, lack of cooperation, and perhaps insufficient muscular control because of senility or Parkinson's disease. These factors all contribute to difficulty in denture construction (Harrison et al. 1992). Conservative modification of the patient's existing dentures can often be preferable to constructing new dentures. Where the dentist is called to the patient who has successfully worn dentures for some years, but has recently developed pain, then modification of the patient's existing dentures can often alleviate the problem.

Problems such as overclosure, poor aesthetics and reduced masticatory function result from severe denture wear. Often, patients also complain of cheek biting, due to infolding of the bunched cheek muscles during mastication. The symptoms of temporomandibular dysfunction are rare.

Ulceration of the buccal sulcus can be due to denture overextension, which arises following bone resorption. This is easily adjusted. Battery-operated motorized straight handpieces (maximum speed of 16,000 rpm) are available from DentalMan (Gentoftegade, Denmark). Their range of equipment also includes a battery-operated mirror light and contra-angle handpiece. Instruments used in the patient's mouth must be transported back to the surgery in rigid containers, with sharp instruments such as needles placed in a sealed rigid container.

## Denture Looseness

The aim of relining and rebasing procedures is to improve adaptation of the denture to the supporting tissues. However, the commonest cause of denture looseness is overextension of the flange. If pulling on the cheeks displaces the denture then flange overextension is suspected. Relining and rebasing dentures will not correct occlusal errors or overextension; it will make them worse. Therefore, when a reline procedure is contemplated, there must be even occlusal contact in the retruded contact position with an adequate interocclusal clearance. Indeed, it is important to check during the impression procedure for the reline technique

that no occlusal errors are introduced. When laboratory processing is complete, a relined complete denture should be remounted on the articulator and the occlusion adjusted to eliminate any occlusal errors.

Tissue conditioners are temporary reline materials. The application of a tissue conditioner to the fitting surface of the denture can be used as a diagnostic procedure. If the patient notices no improvement in denture looseness, it indicates that permanent relining of the dentures may be destined to failure. Tissue conditioners must be replaced or removed after about a week as they become hard, collect food and become unhygienic.

### *Technique for Relining Upper and Lower Dentures*

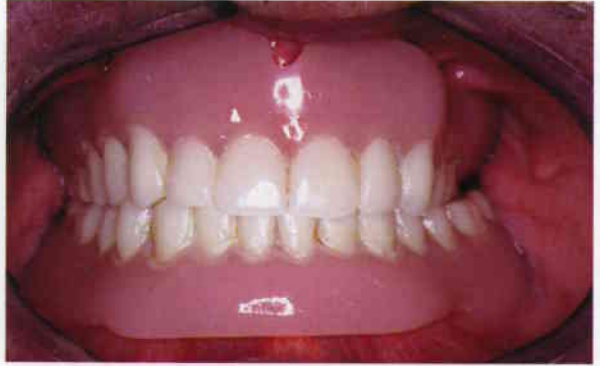Any undercut is removed from the periphery of the upper denture to enable the technician to remove the denture from the poured cast. Where the periphery of the denture is underextended, an isofunctional impression material (GC Corporation, Tokyo, Japan) is added to the flange. This is a waxy, thermoplastic material that is softened over a flame and then applied to the denture periphery. The impression material is tempered in hot water at 45°C, and the denture is then seated in the mouth. Careful muscle trimming allows the periphery to be moulded. The retention and peripheral seal of the modified denture can be assessed. Holes are made in the palatal surface of the upper denture to allow the fluid impression material to escape and prevent an excessive palatal thickness.

A suitable impression material is a low viscosity silicone (which requires an adhesive) or zinc oxide/eugenol paste. The impression material is placed on the fitting surface and periphery of the upper denture and inserted. The patient closes together lightly onto the lower denture to ensure even occlusal contacts are maintained and to prevent an excessive thickness of palatal impression material which will disrupt the occlusion. When the impression material has set, the denture is removed from the patient's mouth. The position of the postdam can be marked with indelible pencil on the palatal surface of the upper impression. Palpation of the tissues in the posterior palatal region with a ball-ended burnisher can indicate the tissue compression possible. Instructions to the laboratory should request that an appropriate depth of postdam is cut and the dentures either relined or rebased in heat curing acrylic resin. A rebase impression technique will replace the polished and fitting surface, whereas a reline impression adds to the palatal thickness of the denture. The lower reline impression is repeated as for the upper.

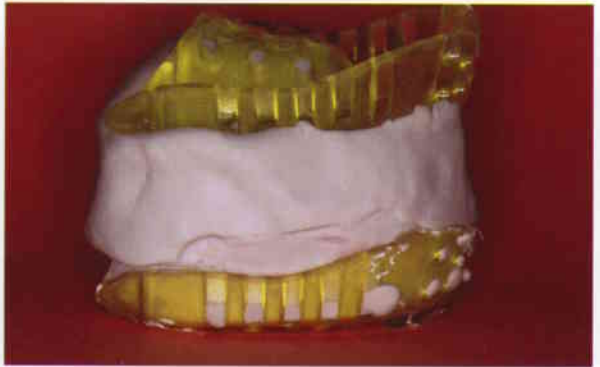
### **Template Dentures**

Elderly frail patients may adapt poorly to new dentures differing markedly from their previous dentures (Fig. 7.4). Variations in the contours of the polished sur-

**Fig. 7.4.** This elderly patient had worn these dentures successfully for many years, but now found them worn and loose. The denture extension, arch form and polished surface were copied in the new dentures using a template denture technique. The posterior teeth had worn, causing a reduction in the overjet, a locked occlusion and denture instability



**Fig. 7.5.** A silicone putty impression was taken of the dentures. This silicone mould was used to produce a copy with wax teeth and an acrylic baseplate. At the next clinical visit, the undercuts in the template dentures were removed and a reline impression in light-bodied silicone was taken. A jaw registration was taken by adding enough soft wax to the lower enough wax to reduce the interocclusal clearance by 2 mm



face and the position of the artificial teeth are inevitable unless a template technique is used. Whichever template method is chosen, modifications to the denture should be included to correct the patient's complaint, while maintaining the good features of the original denture.

Where the original denture is underextended, it can be modified with greenstick compound before duplicating. Laboratory grade silicone putty can be used to form a rigid mould around the old denture (Fig. 7.5). Upon removal of the denture, wax is poured into the impressions of the teeth and then self-curing acrylic resin. The resulting template has wax teeth and an acrylic baseplate. The denture is returned to the patient after removing any greenstick impression compound.

At the next clinical visit, the templates are used to take a reline impression. Following this, the interocclusal clearance is measured and compared with the original dentures. When the interocclusal clearance is acceptable, the retruded contact position is recorded by cutting a small groove on the occlusal surface of the upper template, between the premolar and molar teeth. A little molten wax is placed on the occlusal surface of the lower template, opposite the upper groove, and the patient closes into the wax with the mandible fully retruded. The inter-

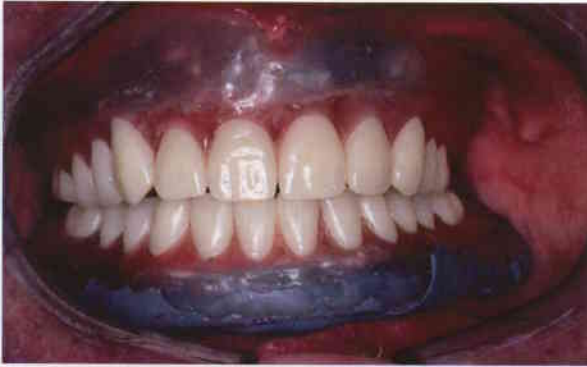

Fig. 7.6. The templates were articulated in the laboratory and the wax teeth replaced by acrylic teeth. At the try-in stage, the extension, arch form and polished surface shape were checked to ensure that they were similar to the old denture. The trial denture was satisfactory, and was therefore processed into heat-cured acrylic

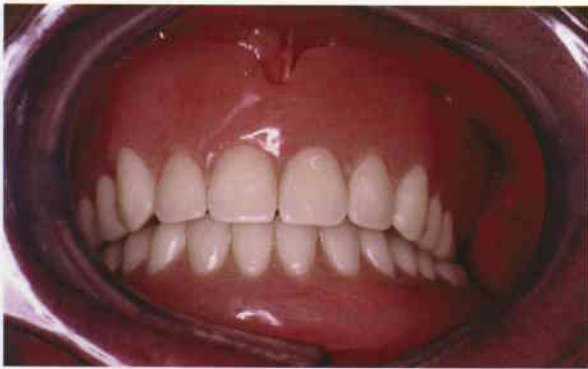

Fig. 7.7. The processed denture was delivered to the patient

occlusal clearance of the patient's existing dentures can be greater than the normal 2–4 mm, as a result of tooth wear and bone resorption. The interocclusal clearance of the new dentures should not differ by more than 3 mm from the old denture because the patient may be unable to adjust to a greater change. The interocclusal clearance is adjusted by adding wax to the lower posterior teeth and the patient closes together in the retruded jaw relation. The position of the occlusal plane can be indicated by scribing a wax line on the buccal surface of the added wax.

The impression material remains on the template denture throughout the jaw registration and try-in stages. In the laboratory, stone casts are poured from the impressions and the templates articulated. The wax teeth are removed alternately and replaced with stock teeth. When all of the teeth have been replaced the template is ready for the trial insertion (Fig. 7.6). The extension of the templates, the occlusion and the aesthetics are all checked and compared with the old denture. In the laboratory, the templates are flaked and the self-curing acrylic baseplates discarded. Acrylic resin dough is then packed into the mould and processed. The finished dentures are returned to the patient (Fig. 7.7).

## Repair of Dentures

A number of measures can be used to prevent denture breakage. During a domiciliary visit, the dentist can assess whether the patient has sufficient manual dexterity to clean the dentures. Ideally, dentures should be cleaned over a bowl of water in case they are dropped. This is especially important in patients with poor manual dexterity, e.g. as a result of arthritis, who cannot grasp small brushes. Toothbrush handles can be modified using silicone impression material to allow the patient to grasp the brush better. Patients should be warned that squeezing together the sides of the lower denture during cleaning so that it flexes about the midline will eventually cause breakage.

Repairing with heat-cured acrylic resin produces a stronger denture. If self-curing acrylic resin is used to repair the denture, crazing or small cracks in the denture can form if methyl methacrylate monomer contacts the denture during repair. This can cause localized denture weakness. However, despite this, self-curing acrylic is routinely used because it is convenient and cheap.

If the broken denture parts can be reassembled accurately, then they can be transferred to the laboratory for repair. When there are many small pieces or parts of the broken denture that have been lost, then a new denture may be indicated. If an impression of the denture in the patient's mouth is required to locate the pieces together, it is important to prevent inadvertent movement of the denture during this procedure.

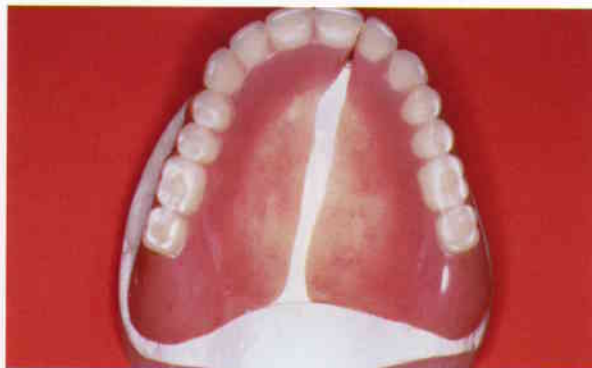## Stages Involved in Denture Repair

Where the denture has broken into two pieces, they can usually be placed together accurately using cyanoacrylate glue and then transferred to the laboratory. A plaster cast of the denture-fitting surface is made, after blocking out undercuts with damp cotton wool. The denture is removed from the cast and the area surrounding the break roughened with a dental stone (Fig. 7.8, p. 104). A separating medium is applied to the plaster and the denture replaced on the cast. Self-curing acrylic is flowed into the break and cured under pressure in a hydroflask for 10 min. The denture is then polished and returned to the patient (Fig. 7.9, p. 104).

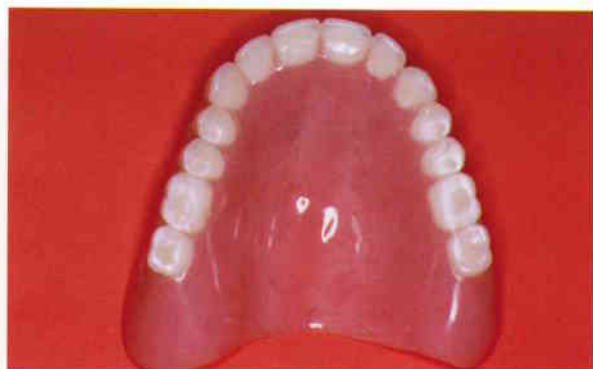## Other Causes of Fractured Dentures

Retaining uninfected tooth roots as overdenture abutments has the advantages of preserving alveolar bone, improving support and providing proprioception. The roots are prepared in a dome-shape, to a height of 2 mm above the gingival margin. However, the thin layer of acrylic denture base above the tooth root is often prone to fracture. During occlusal loading there is a differential compressibility of the tissues, with the result that the denture sinks into the underlying mucosa





**Fig. 7.8.** The fractured denture parts were located together and a cast poured into the fitting surface of the denture. The edges of the denture break were bevelled to disguise the margin of the acrylic added. Separating medium was applied to the plaster cast and self-curing acrylic resin flowed into the break



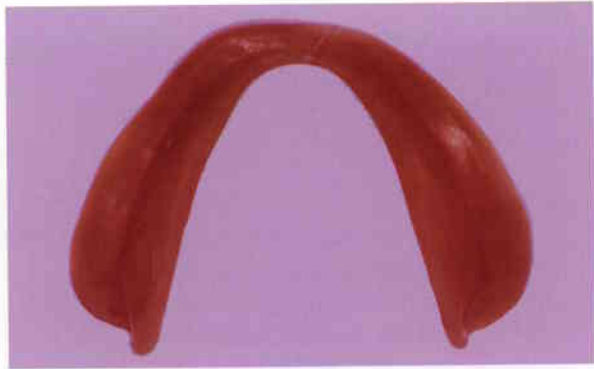**Fig. 7.9.** The acrylic was cured under pressure and polished, and the denture returned to the patient

leaving the roots to bear the occlusal load. Processing the denture in high-impact resistant rubber-modified acrylic (such as Metrocyl Hi, manufactured by Metrodent, Huddersfield, UK) may provide the additional strength required. Alternatively, a special impression technique may be used which avoids imposing additional force on the abutment teeth during occlusal loading. The denture-bearing mucosa is compressed using a zinc oxide/eugenol impression material in a close-fitting special tray. The roots protrude through holes cut in the tray and plaster of Paris impression material is placed over the exposed roots. When the impression material has set it is removed from the patient's mouth and cast.

Patients often complain that their dentures broke when they were eating the softest material and therefore applying the smallest of occlusal loads. It is the progression of a crack through the acrylic combined with continual denture flexure that eventually causes fracture. Placement of the upper posterior teeth of dentures too far buccally can cause unnecessary flexure of the denture base. However, a thin baseplate due to excessive denture relief or extreme thinning of the palatal acrylic to eliminate symptoms of nausea, can also predispose the denture to fracture. Due to encroachment of the mentalis muscle onto the resorbed ridge, the anterior flange of the lower denture may also be excessively thin (Fig. 7.10).



**Fig. 7.10.** With severe resorption, the mentalis muscle encroaches on the crest of the lower ridge. When this is combined with relief over the genial tubercles, the anterior part of the lower denture tends to be made thin and is prone to fracture



Acrylic denture teeth may lack adhesion with the acrylic base if separating medium is inadvertently applied to them during the laboratory processing stage of denture construction. Similarly, if porosity is introduced into the denture due to an incorrect processing temperatures or a too-rapid cure cycle, the denture base may be prone to fracture.

## References

- Appolino I, Carabellese C, Frattola A, et al (1997) Influence of dental status on dietary intake and survival in community-dwelling elderly subjects. *Age Ageing* 26:445-455
- Bengtsson A, Olsson T, Ren3/4 N, Carlsson GE, Dahlbom U (1996) Frequency of edentulism and identification marking of removable dentures in long-term care units. *J Oral Rehab* 23:520-523
- Burke FJ, McCord JF, Hoad-Reddick G, Cheung SW (1995) Provision of domiciliary dental care in a U.K. urban area: results of a survey. *Prim Dent Care* 2:47-50
- Cunningham M, Hoad-Reddick G (1993) Attitudes to identification of dentures: the patient's perspective. *Quintessence Int* 24:267-270
- Fiske J, Graham T, Gelbier S (1986) Denture identification for elderly people. *Br Dent J* 161:448-449
- Harrison A, Huggett R, Watson CJ, Beck CB (1992) A survey of complete denture prosthetics for the elderly, the handicapped and difficult patients. *Br Dent J* 172:51-56
- Heath JR (1987) Denture identification - a simple approach. *J Oral Rehab* 14:147-163
- Heath JR, Zoitopoulos L, Griffiths C (1988) Simple methods for denture identification: a clinical trial. *J Oral Rehab* 15:587-592
- Hoad-Reddick G, Grant AA, Griffiths CS (1990) Investigation into the cleanliness of dentures in an elderly population. *J Prosthet Dent* 64:48-52
- Hutchins DW, Parker WA (1973) A clinical evaluation of the ability of denture cleaning solutions to remove dental plaque from prosthetic appliances. *N Y State Dent J* 39:363
- Lamy M, Mojon Ph, Kalkakis G, Legrand R, Butz-Jorgensen E (1999) Oral status and nutrition in the institutionalised elderly. *J Dent* 27:443-448

## Subject Index

- Aesthetics 38, 51, 54, 70, 83, 93, 99  
Ageing 42, 93  
Alar-tragal plane 39  
Alginate 19, 22  
Angular cheilitis 4  
Anterior open bite 70  
Anterior tooth arrangement 65-67  
Appearance 14, 52, 65-69  
Articulating paper 7, 81  
Articulators 70-72
- Balanced articulation 35, 38, 69, 90  
Balanced occlusion 50, 82  
Balancing side 36  
Ball-ended burnisher 73, 100  
Biometric guidelines 48  
Bleaching *see* whitening of denture  
Border moulding 19, 22-24  
Buccinator muscle 59  
BULL rule 36, 82  
Burning mouth syndrome 93
- Camper's plane *see* alar-tragal plane  
Candida albicans 8, 13  
Candidiasis 93  
Canine lines 39  
Centre line on upper occlusal rim 40  
Chairside relines 10, 12  
Cheek biting 89  
Closest speaking distance 72-73  
Colour of labial flange 73  
Condylar guidance 36, 69-72  
Condyle 35  
Coronoid process 22  
Cuspless posterior teeth 52, 70
- Denture fixative 84  
Denture fracture 103-105  
Denture granuloma 5  
Denture marking 98  
Denture repair 103  
Denture space 55  
Denture stomatitis 8-12, 84, 96  
Diabetes mellitus 4, 93  
Disinfection procedures 21  
Dry mouth 84
- Electromyography 56  
External oblique ridge 26, 87
- Facebow 72, 81-82  
Floor of the mouth 5, 27  
Foveae palatinae 73  
Fox occlusal plane guide 39, 65  
Freeway space *see* interocclusal clearance  
Frenal attachments 13, 22
- Gagging 3, 31  
Genial tubercle 25, 74, 91  
Genioglossus muscle 25
- Hamular notch 22, 23, 73,  
Hinge axis, arbitrary 81  
History taking 2-14, 86  
Hypochlorite solution 10

- Impression techniques 20-21  
Incisal guidance 35  
Incisive papilla 45, 92  
Instructions to the patient 83-84  
Instructions to the technician  
    37, 74-75  
Intercuspal occlusion 35  
Intercuspal position 35  
Interocclusal clearance 40  
Interocclusal wax record 3  
Isofunctional impression material  
    100
- Labial flange 73  
Labial sulcus 26  
Labiomental groove 68  
Lingualised occlusion 52, 70  
Lining materials, resilient 90-91  
Lip support 36
- Mandibular rest position 40  
Medical history 3-4  
Metal template guides 52  
Miconazole gel 9  
Minute stains system 83  
Modiolus 55  
Mucoperiosteum 18, 90  
Mucosa 18  
Mylohyoid muscle 27  
Mylohyoid ridge 5, 26, 74, 90, 91
- Nasolabial angle 37-38  
Nausea 3, 5, 104  
Neuromuscular control 3, 4  
Neutral zone *see* denture space  
Nonanatomical teeth 50-51
- Occlusal pivot appliances 50  
Occlusal plane 38-39, 47  
Occlusal premature contacts 36, 80
- Occlusal vertical dimension 40, 41  
Occlusal rims 37  
Overbite 36, 51  
Overclosure 68  
Overdenture 103  
Overextension 2, 23, 26, 64, 86, 88, 92,  
    99
- Pain 28, 52, 80, 86-90  
Palatoglossal muscle 27  
Papillary hyperplasia 5, 8  
Parotid papilla 39  
Peripheral seal 6, 13, 27, 56, 64, 100  
Piezogram 56  
Plaster of Paris impression  
    technique 20, 22, 29-30  
Postdam 18, 73, 74  
Pressure relief cream 80  
Prognosis of treatment 3, 14  
Pterygomandibular raphe 55, 59
- Relining 2, 100  
Remounting procedures 81-82  
Rest vertical dimension 40, 41  
Retromolar pad 6, 25, 59, 87  
Retromylohyoid space 6, 26, 27  
Retruded contact position 35, 41  
Review, annual 84  
Ridge, fibrous 74
- Saliva 4, 41  
Selective grinding 76, 82  
Selective pressure impression  
    technique 28-30  
Speech 84, 91-92  
Support for dentures 89, 103  
Swallowing difficulties 88
- Template denture 100-102  
Temporomandibular joint 35

- Tin foil relief 74  
Tissue conditioner 10, 100  
Tissue hyperplasia 13  
Toothbrush, modified 103  
Torus 5  
Training plate 31  
Tuberosities, enlarged 14
- Undercuts 74  
Underextension 19, 23, 83
- Vibrating line 18, 23, 74  
Vitamin B deficiencies 93
- Wax stops for impression taking 23  
Wear 6, 42, 50, 99  
Whitening of denture 97  
Williams classification 42  
Willis gauge 40  
Working side 35
- Zinc oxide and eugenol impression  
21, 26-28, 100, 104